European Journal of Human Genetics (2002) 10, 91 – 94
© 2002 Nature Publishing Group All rights reserved 1018-4813/02 $25.00
www.nature.com/ejhg

PRACTICAL GENETICS

Merosin-deficient congenital muscular dystrophy, autosomal recessive (MDC1A, MIM#156225, LAMA2 gene coding for α2 chain of laminin)

Valérie Allamand*,[1] and Pascale Guicheney[1]

[1]*INSERM U523, Institut de Myologie-Bâtiment Joseph Babinski, Groupe Hospitalier Pitié-Salpétrière, 47 Boulevard de l'Hôpital, 75651 Paris Cedex 13, France*

Congenital muscular dystrophies (CMDs) are a highly heterogeneous group of neuromuscular disorders. A subgroup displays a specific deficiency in a protein of the extracellular matrix, the α2 chain of laminin-2 (merosin). A number of mutations in the gene encoding this protein have been identified in patients who present with a severe phenotype and white matter changes.
European Journal of Human Genetics (2002) **10,** 91 – 94. DOI: 10.1038/sj/ejhg/5200743

Keywords: congenital muscular dystrophy; laminin; merosin-deficiency; extracellular matrix; skeletal muscle

Clinical definition

Congenital muscular dystrophies (CMD) are a group of neuromuscular disorders with severe muscle hypotonia at birth or within the first months of life, generalised muscle weakness, contractures of variable severity and delayed motor milestones. Histological changes in muscle biopsies consist of marked connective tissue proliferation, large variation in the size of the muscle fibres as well as some necrotic and regenerating fibres in early stages of the disease.

Merosin-deficient CMD is a severe form characterised by an absence of laminin α2 chain (formerly named merosin) around muscle fibres, elevated serum creatine kinase (CK), especially in the early months of life, no independent ambulation due to weakness and contractures, respiratory insufficiency which could need tracheotomy. Most patients have normal intelligence but some have been reported to show moderate mental retardation and epilepsy. They form a clinically homogeneous subgroup, in contrast to partial merosin deficiency cases who are less frequent, of variable severity but generally less severe.[1]

*Correspondence: V Allamand, INSERM U523, Institut de Myologie-Bâtiment Joseph Babinski, Groupe Hospitalier Pitié-Salpétrière, 47 Boulevard de l'Hôpital, 75651 Paris Cedex 13, France. Tel: 01 42 16 57 20; Fax: 01 42 16 57 00; E-mail: v.allamand@myologie.chups.jussieu.fr
Received 12 July 2001; accepted 31 August 2001

Diagnosis

It is usually made by the clinical features and muscle biopsy examination. Immunocytochemically, laminin α2 chain is deficient, with overexpression of α4 and α5 chains in the basal lamina surrounding myofibres. Integrin α7β1 and α-dystroglycan, two functional laminin receptors show secondary reduction.[2,3] The use of several antibodies directed against different regions of laminin α2 chain allows a precise distinction between complete and partial deficiency.[4] Skin biopsies may be used instead of the muscle biopsy to confirm a complete laminin α2 chain deficiency.

Striking diffuse brain white matter changes in merosin deficient CMD patients generally appear after the first 6 to 12 months of life. Their detection by magnetic resonance imaging (MRI) has now become a very useful diagnostic tool, including in cases of partial deficiency.

Prenatal diagnosis can be made by determination of at-risk haplotypes using various intra- and extragenic markers, and also by immunocytochemical analysis of trophoblast, but only in the case of complete merosin deficiency.[5]

Most important differential diagnoses

Complete merosin deficiency is a well-defined entity without genetic heterogeneity, and its diagnosis is clear-cut.

Partial merosin deficiency can be due to *LAMA2* defects or to other causes. To our knowledge, all cases with partial merosin deficiency, normal intelligence and white matter changes are due to a primary *LAMA2* defect. But a few cases with primary partial merosin deficiency may present a slight mental retardation, epilepsy, and/or very mild occipital cortex or cerebellum abnormalities in addition to the characteristic white matter changes. Their precise diagnosis is then difficult in absence of a molecular confirmation, as they can be mistaken for other disorders.

Some CMD cases with partial merosin deficiency and normal or subnormal intelligence without white matter changes are unlinked to *LAMA2*. They comprise cases with calf pseudohypertrophy and early respiratory failure for which a locus (MDC1B) has been assigned to chromosome 1q42, and also cases unlinked to 1q42 who do or do not develop severe macroglossia due to mutations in the Fukutin-related protein gene.[3,6]

Partial deficiency observed also in Fukuyama CMD (mostly prevalent in Japan), Muscle-Eye-Brain disease, Walker-Warburg Syndrome is associated with moderate to severe mental retardation and brain and ocular abnormalities, which usually permit the diagnosis of these diseases.

Disease frequency

The prevalence of CMDs has been estimated to be 0.7/100 000 in a sample from north-east Italy.[7] Merosin-deficient CMD accounts for about 30% of the CMD cases in European countries, but only 6% in Japan.

Gene

The human *LAMA2* gene is located on 6q22-23, spans over 260 kb and consists of 64 exons. mRNA is about 9.5 kb.

Function of the protein

Laminins are a family of large extracellular trimeric glycoproteins. Five α chains, 3 β and 2 γ have been described to assemble and form at least 12 distinct heterotrimeric molecules. They form supramolecular structures by auto-aggregating or by interacting with other components of the basal lamina. The C-terminal ends of all α chains contain domains crucial for their interaction with membrane receptors.

Laminin-2 and laminin-4 are composed of three chains: one heavy (α2) and two light chains (β1 or β2, respectively, and γ1). They are expressed in the basal lamina of striated muscles and peripheral nerves. Laminin-2 has been shown to be necessary for myogenesis as well as for the survival and stability of myotubes *in vitro*. A massive muscle fibre degeneration with scattered positive signals for apoptosis occurs in the very early stage of the disease.[2]

Laminin α2 chain is expressed in numerous tissues including skeletal muscle fibres, Schwann cells, synaptic basal lamina of peripheral nerves, heart, trophoblast and skin. The α2 chain is involved in cellular attachment, neurite growth and the migration of Schwann cells.

The α2 chain of laminin consists of six domains: I and II are part of the long arm; IIIa, IIIb and V contain cystein-rich EGF-like repeats and are predicted to have rigid rod-like structures; IVa, IVb and VI are predicted to form globular structures. The globular C-terminal region (G) is constituted of five internal homologous repeats and contains the interaction sites for membrane receptors that are, in striated muscle cells, α-dystroglycan and integrin α7β1.[8]

Animal model

The most commonly used animal models for merosin-deficient CMD are the long-known spontaneous mouse strains *dy* (*dystrophia muscularis*) and dy^{2J} which present a muscle pathology and a dysmyelination of the peripheral nervous system due to a complete and partial deficiency in the α2 chain of laminin, respectively. The *dy* mouse is the most severely affected and the mutation responsible for its phenotype still remains unknown. The mouse α2 chain gene (*Lama2*) has been genetically linked to the same region of mouse chromosome 10 to which the *dy* locus has been mapped. The mutation responsible for the dy^{2J} phenotype has been identified: it is a point mutation (G→A) in a consensus donor splice site leading to abnormal splicing and expression of six mRNA species. The M0 variant appears to be the predominant transcript and is translated into a protein lacking 57 in domain VI.

In addition, two knockout lines were generated (dy^{3K} and dy^{W}). These mice present a severe phenotype and have a reduced life span.[9]

Mutations

Since the identification of the first mutations leading to complete merosin deficiency in 1995, a number of mutations have subsequently been reported (Figure 1).[2,5,10]

Analysis of the laminin α2 chain cDNA or the *LAMA2* gene itself showed that nucleotide substitutions, small deletions, or insertions induce complete merosin deficiency. Most of the mutations are localised in the N-terminal domain (exons 1–31) and are predicted to produce truncated proteins. A 2 bp deletion, 2098delAC (703X), has been repeatedly found in several studies.[2,5,10] A nonsense mutation, C967X, has also been identified in several Italian families. Some larger deletions have been reported.

The spectrum of the phenotypes of CMD patients with partial merosin deficiency is wide and caused by homozygous missense mutations, homozygous in-frame deletions, or a missense or an in-frame deletion associated to a nonsense mutation. Changes of conserved cystein residues

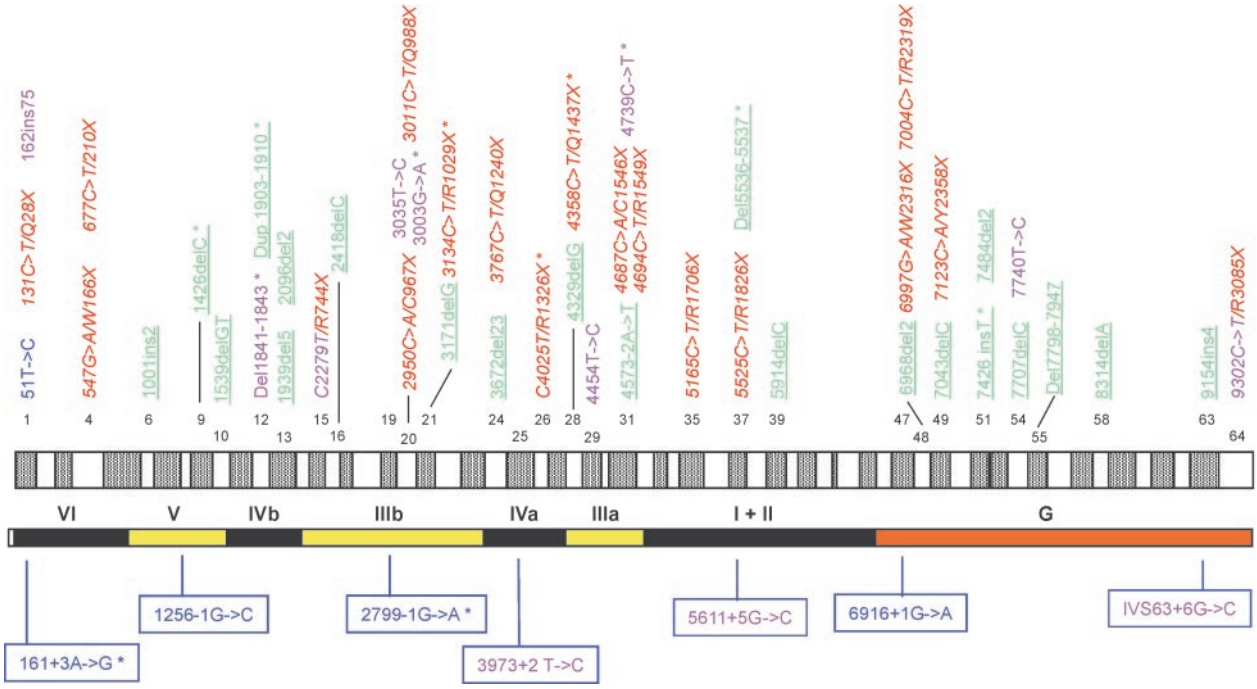

Figure 1 Schematic representation of all mutations in the *LAMA2* gene causing merosin-deficient DMC. Mutations are scattered along the coding sequence containing 64 exons (only those containing mutations are numbered) and affect different domains of the protein which are represented below the coding sequence. Mutations are of different kinds: nonsense (in red, italicized), frameshift (in green, underlined) or splice site (in blue, boxed). Mutations causing a partial deficiency of the laminin α2 chain are indicated in purple. Asterisks refer to novel unpublished mutations identified by our group.

of the short arm of the protein induce partial deficiency probably by inducing proteolysis or instability of the scaffold.

Intronic and exonic primers have been designed to analyse *LAMA2* gene from cDNA or genomic DNA[11] but the protein truncated test (PTT) is a more appropriate method to detect nonsense mutations in such a large gene.[10]

Treatment

To date no treatment available but the conditions of life are improved by physiotherapy to reduce contractures and arthrodesis to limit deformation. Ventilatory support and tracheotomy, when necessary, have contributed to a marked increase of the life expectancy for the most severely affected patients.

Two strategies have been tested in the murine models *dy* and dy^{2J} to correct the phenotypes and have led to partial positive results. Myoblast transplantation, as well as transgenic experiments, have allowed renewed expression of the laminin α2 chain and amelioration of the muscle pathology to a certain extent but these techniques clearly cannot so far be applied to human.[9]

References

1 Tomé FMS: The saga of congenital muscular dystrophy. *Neuropediatrics* 1999; **30**: 55–65.
2 Hayashi YK, Tezak Z, Momoi T *et al*: Massive muscle cell degeneration in the early stage of merosin-deficient congenital muscular dystrophy. *Neuromuscul Disord* 2001; **11**: 350–359.
3 Muntoni F, Blake D, Brockington M *et al*: 85th ENMC International Workshop on Congenital Muscular Dystrophy 6th International CMD Workshop 1st Workshop of the Myo-Cluster Project 'GENRE' 27–28th October 2000, Naarden, The Netherlands. *Neuromuscul Disord* 2001; **12**: 69–78.
4 He Y, Jones KJ, Vignier N *et al*: Mild congenital muscular dystrophy with primary partial laminin α2 chain deficiency: molecular study. *Neurology* 2001; **57**: 1319–1322.
5 Guicheney P, Vignier N, Zhang X *et al*: PCR based mutation screening of the laminin alpha2 chain gene (LAMA2): application to prenatal diagnosis and search for founder effects in congenital muscular dystrophy. *J Med Genet* 1998; **35**: 211–217.
6 Brockington M, Blake DJ, Prandini P *et al*: Mutations in the Fukutin-Related Protein Gene (FKRP) cause a form of congenital muscular dystrophy with secondary laminin α2 deficiency and abnormal glycosylation of α-dystroglycan. *Am J Hum Genet* 2001; **69**: 1198–1209.
7 Mostacciuolo ML, Miorin M, Martinello F, Angelini C, Perini P, Trevisan CP: Genetic epidemiology of congenital muscular dystrophy in a sample from north-east Italy. *Hum Genet* 1996; **97**: 277–279.

8 Miyagoe-Suzuki Y, Nakagawa M, Takeda S: Merosin and congenital muscular dystrophy. *Microsc Res Tech* 2000; **48**: 181–191.
9 Allamand V, Campbell KP: Animal models for muscular dystrophy : valuable tools for the development of therapies. *Hum Mol Genet* 2000; **9**: 2459–2467.
10 Perogaro E, Marks H, Garcia CA *et al*: Laminin α2 muscular dystrophy. Genotype/phenotype studies of 22 patients. *Neurology* 1998; **51**: 101–110.
11 Helbling-Leclerc A, Guicheney P: Analysis of the LAMA2 gene in merosin-deficient congenital dystrophy; in Anderson and Bushby, (eds). Methods of Molecular Medecine. Totowa: Humana Press Inc., 2000, pp. 199–218.