

Review

Congenital muscular dystrophies: New aspects of an expanding group of disorders

Matthew T. Lisi, Ronald D. Cohn*

McKusick-Nathans Institute of Genetic Medicine, Department of Pediatrics and Neurology, Johns Hopkins University School of Medicine, 600 N Wolfe Street, Blalock 1008 Baltimore, MD 21287, USA

Received 13 July 2006; received in revised form 11 September 2006; accepted 13 September 2006

Available online 20 September 2006

Abstract

The congenital muscular dystrophies comprise a genetically and clinically heterogeneous group of disorders characterized by early onset of progressive muscle weakness and often involvement of other organ systems such as the brain and eyes. During the last decade, significant progress has been made to further characterize various forms of congenital muscular dystrophies based on their specific genetic and clinical appearance. This review represents an overview of the recent accomplishments as they relate to clinical, diagnostic, pathogenetic and therapeutic aspects of congenital muscular dystrophies.

© 2006 Elsevier B.V. All rights reserved.

Keywords: Muscular dystrophy; Laminin- α 2; Dystroglycan; Selenoprotein N; Integrins

1. Introduction

Congenital muscular dystrophy (CMD) was first described in 1903 by Frederick Batten [1], for a more detailed historical overview see Tome and Voit [2]. Given the recent improvement of molecular technologies, the classification of CMD's has significantly changed from phenotype driven towards a more molecular based categorization (see Table 1). So far up to eleven genes are known to cause various forms of CMD and several clinically distinct entities of CMD's which are not linked to any of the described forms emphasize that the number of causative

genes associated with CMD will increase in the near future [3,4].

2. MDC1A and laminin- α 2

MDC1A is an autosomal recessive form of congenital muscular dystrophy caused by deficiency in laminin- α 2 [5,6]. Laminins are heterotrimers consisting of an α , β , and γ subunit, and variants of each combine to form tissue and developmentally specific isoforms. Laminin- α 2 is encoded by the LAMA2 gene (6q22–q23), and is the α subunit of laminin-2 which is also referred to as merosin [7,8]. Various mutations in the LAMA2 gene have been found to cause a deficiency in merosin, either in quantity or function [5,9].

Laminin- α is comprised of the α 2, β 1, and γ 1 subunits (Fig. 1a), and is found at the basement membrane of striated muscle, placental trophoblast cells, and peripheral nerve Schwann cells [10–12]. Myotendinous junctions and neuromuscular junctions represent two major sites of expression for laminin- α 2, although it is widespread throughout the basal lamina [7]. Laminin-4 (α 2, β 2, γ 1) is a prevalent laminin that differs from merosin by the replacement of the β 1 subunit with a β 2. This isoform is expressed in a developmentally regulated

Abbreviations: MDC1A, congenital muscular dystrophy type 1A; LAMA2, laminin- α 2 gene; DGC, dystrophin–glycoprotein complex; MDC1D, congenital muscular dystrophy type 1D; FKRP, fukutin-related protein; MDC1C, congenital muscular dystrophy type 1C; LGMD2I, limb-girdle muscular dystrophy type 2I; FCMD, Fukuyama congenital muscular dystrophy; POMGnT1, *O*-linked mannose β 1,2-*N*-acetylglucosaminyl-transferase; MEB, muscle–eye–brain disease; POMT1, protein *O*-mannosyltransferase I; WWS, Walker–Warburg syndrome; UCMD, Ullrich congenital muscular dystrophy; RSMD1, rigid-spine muscular dystrophy; SEPNI, selenoprotein N; ITGA7, alpha7 integrin gene

* Corresponding author. Tel.: +1 410 955 3071; fax: +1 410 614 9246.

E-mail address: rcohn2@jhmi.edu (R.D. Cohn).

Table 1
Congenital muscular dystrophies associated with genetic causes

| Disease | Gene symbol | Protein | Clinical features |
|---|--|-------------------------|--|
| Merosin deficient CMD (MDC1A) | <i>LAMA2</i> | laminin- α 2 | Muscular dystrophy, respiratory insufficiency and nocturnal hypoventilation, white matter changes, neuronal migration abnormalities and mental retardation (rare) seizures, peripheral neuropathy, CK elevated |
| MDC1B | linked to 1q42? | ? | Facial weakness, diaphragmatic involvement with early respiratory failure, rigid spine, secondary laminin α 2 deficiency |
| Rigid spine syndrome (RSM1) | <i>SEPN1</i> | selenoprotein-1 | Muscular dystrophy, axial hypotonia and weakness, lumbar scoliosis and cervical spine stiffness, respiratory failure due to skeletal abnormalities and diaphragmatic weakness, CK normal or mildly elevated |
| Integrin α 7 congenital myopathy | <i>ITGA7</i> | integrin α 7 | Mild muscular dystrophy/myopathy, mental retardation, torticollis, mildly elevated CK |
| Ullrich's disease (1,2,3) | <i>COL 6A1</i> <i>COL 6A2</i> <i>COL 6A3</i> | collagen VI | Neonatal muscle weakness, kyphosis of spine, joint contractures, torticollis, hip dislocation, hyperextensibility of distal joints, follicular hyperkeratosis, cheloid formation, invariable respiratory insufficiency, normal intelligence, CK normal or mildly elevated, |
| MDC1D | <i>LARGE</i> | LARGE | Muscular dystrophy, profound mental retardation, subtle brain abnormalities |
| Walker–Warburg syndrome | <i>POMT1</i> <i>POMT2</i> | POMT1 POMT2 | Muscular dystrophy, type II lissencephaly/agryia, hydrocephalus, eye abnormalities, life expectancy <3 years, CK elevated |
| Muscle–eye–brain disease | <i>POMGnT1</i> | POMGnT1 | Muscular dystrophy, broad clinical phenotype, significant hypotonia, eye abnormalities and abnormal neuronal migration |
| Fukuyama CMD | <i>FKTN</i> | Fukutin | Muscular dystrophy, severe brain involvement with mental retardation, cardiomyopathy, seizures, eye abnormalities |
| MDC1C | <i>FKRP</i> | Fukutin-related protein | Muscular dystrophy, congenital weakness and hypotonia, calf and tongue hypertrophy, shoulder muscle wasting, cardiomyopathy, severe end of the spectrum: structural brain changes, retinal changes with blindness, CK elevated |

fashion that becomes restricted to the basal lamina of the synapse. The limited synaptic expression of β 2 in adulthood drives this pattern of regionalization [13]. Laminin- α 2 is also present at basal lamina of neural vasculature, although it is not expressed in the vasculature of other tissues [14].

Laminins have a variety of functional roles. In almost every tissue type laminins form an essential structural element of the basement membrane. They bind at the cell surface to both dystroglycan and integrin where they serve as part of the structural scaffold and as an active signaling cascade modifying cell differentiation, tissue survival and composition [7]. The binding of laminin- α 2 to α -dystroglycan depends on the proteolytic cleavage of laminin into 300 kDa and 80 kDa segments, and without this cleavage binding is reduced by as much as 10 fold [15]. The relationship between laminin and its binding partners appears to be more complex than a simple physical tether. Dystroglycan and integrins are critical for the polymerization of laminin- α 2, and the ultrastructural organization of the receptors is dependent on laminin [16]. Laminin- α 2 has additional functions in the brain that are not fully understood. This is supported by the white matter changes evident in patients with a deficiency of laminin- α 2 [7] (see below).

2.1. Clinical manifestations and diagnosis

Patients with MDC1A suffer from a variety of symptoms beginning in infancy or early childhood including hypotonia, kyphoscoliosis, and joint contractures. Patients have delayed motor milestones and often do not achieve ambulation. Respiratory insufficiency is a common manifestation that may progress to the requirement of supportive ventilation. Serum creatine kinase levels are markedly elevated by as much as 150 times above the normal level [3,17,18].

The brain is affected in numerous ways with notable variation in severity. Normal intelligence is found in a majority of patients, although some present with seizures and mental retardation [18]. After 6 months of life, most MDC1A patients have a specific pattern of white matter changes on brain MRI with increased signal intensity on T2-weighted images [4]. In addition, patients show signs of dysmyelinating motor neuropathy with reduced nerve conduction velocity [4]. Cerebellar hypoplasia has been observed in patients with and without intellectual involvement [19]. In some cases autopsy and MRI revealed occipital agyria and polymicrogyria, a clear display of the extreme variation in phenotype [20,21]. Cardiac failure seems to be a rare feature of this disorder [22], although echocardiographic evidence of left ventricular hypokinesia has been observed [23]. Visual function is however affected, abnormal responses of visual and somatosensory evoked potentials [24] and partial external ophthalmoplegia with limited ocular movements have been reported [25].

Diagnosis of MDC1A is made by muscle biopsy and molecular genetic testing. Skeletal muscle abnormalities include dystrophic changes such as muscle fiber necrosis, with signs of ongoing degeneration and regeneration. Often, a significant increase in endomysial connective tissue around muscle fibers is present indicating end-stage muscle disease. Immunohistochemical studies focus on the expression pattern of the C- and N-terminal form of laminin- α 2. A subset of patients show absence and/or marked reduction in the C-terminal 80 kDa cleavage product of laminin- α 2 while others display only a reduction in the N-terminal 300 kDa portion [26,27]. Patients with preserved C-terminal expression and reduced N-terminal expression of laminin- α 2 exhibit a milder phenotype [26]. Therefore, antibodies directed against the C- and N-terminal portion of laminin- α 2 must be used to accurately assess a particular

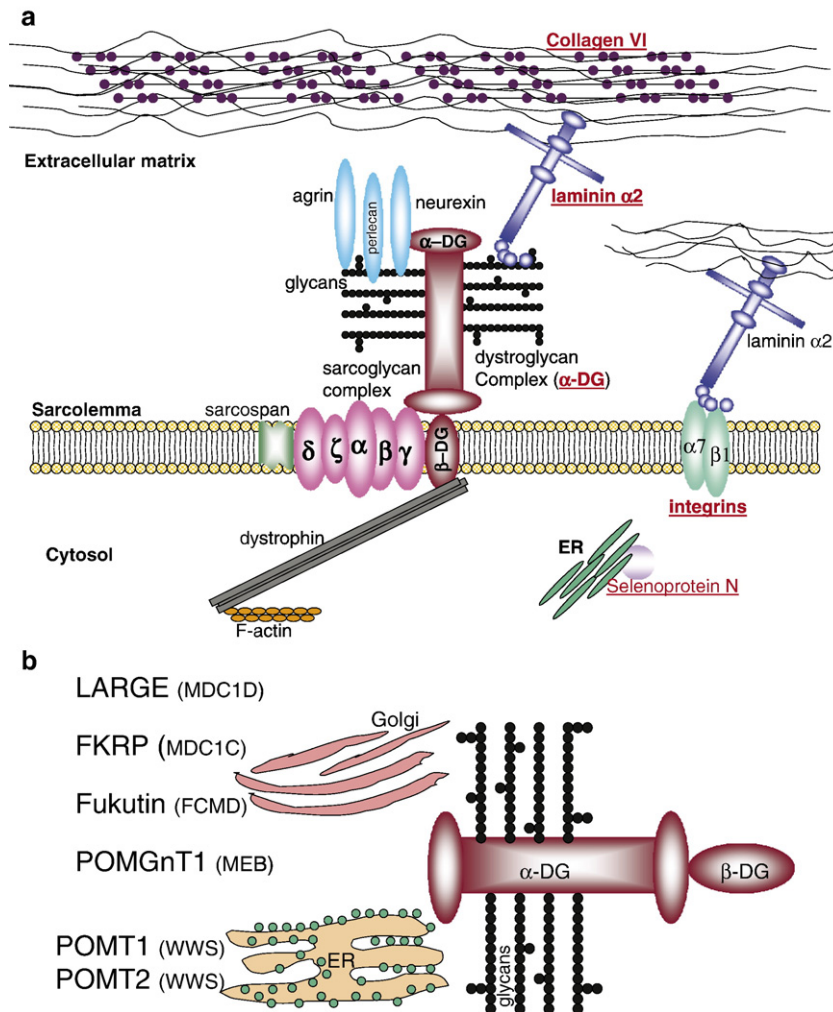


Fig. 1. (a) Overview of the proteins associated with congenital muscular dystrophies. Highlighted proteins are known to cause various forms of congenital muscular dystrophies. ER, endoplasmic reticulum. (b) Overview of proteins involved in the glycosylation of α -dystroglycan. Abbreviations see text; ER, endoplasmic reticulum.

patient's protein expression profile [26,27]. Laminin- $\beta 2$ is also reduced at the sarcolemma of laminin- $\alpha 2$ deficient tissues making it an effective secondary marker [28]. Other secondary protein abnormalities include integrin $\alpha 7$ which is reduced at the sarcolemma as well as laminin- $\alpha 4$ and $\alpha 5$ which display an increased sarcolemmal expression pattern [29–31]. Skin biopsy can be an assistive diagnostic tool as laminin- $\alpha 2$ is reduced at the dermal epidermal junction in cases of MDC1A [32].

Prenatal diagnosis is available by chorionic villus sampling (CVS) in families with a child previously diagnosed with MDC1A [33–36]. Absent laminin chains, normally expressed in the basal lamina of trophoblasts and intramesodermal blood vessels, indicate MDC1A in the fetus [36]. Reduced laminin- $\alpha 2$ could be the secondary result of another gene defect, and this emphasizes the need for molecular studies in conjunction with CVS for accurate diagnosis [33,34,37].

Recently an autosomal recessive form of congenital muscular dystrophy, characterized by proximal weakness, generalized muscle hypertrophy, rigidity of the spine, and contractures of the Achilles tendon, was described in a consanguineous family from the United Arab Emirates. Early

respiratory failure resulting from severe diaphragmatic involvement was present. Serum creatine kinase levels were grossly elevated, and muscle-biopsy samples showed dystrophic changes with secondary laminin- $\alpha 2$ deficiency. This disorder however was linked to chromosome 1q42 [38].

2.2. Pathogenesis and genetics

The Gene LAMA2 encodes for laminin- $\alpha 2$ and is located at loci 6q22–q23 [11]. Complete laminin- $\alpha 2$ deficiency is responsible for almost half of all cases of CMD and follows a recessive pattern of inheritance. Not all cases of laminin- $\alpha 2$ deficiency can be associated with definitive causative mutations in LAMA2, although the majority of patients with clinical manifestations show some change in the LAMA2 sequence that represents putative mutations [39]. Mutations in LAMA2 can cause partial or complete deficiency in laminin- $\alpha 2$, with most mutations causing the latter [40]. Severity of phenotype is highly dependent on the type of mutation with complete absence of protein leading to severe, early-onset phenotype, and partial deficiency leading to variable expression of disease [41,42] (Fig.

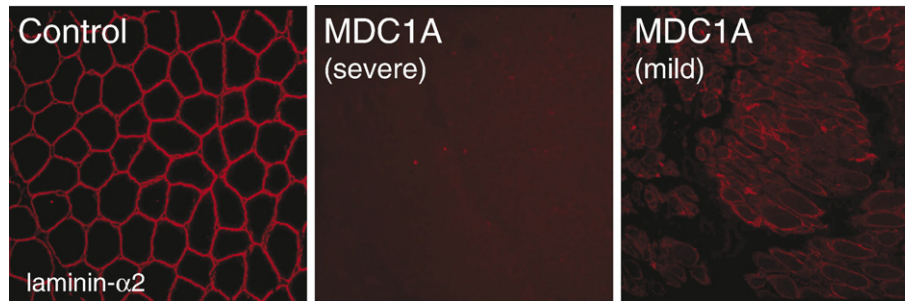


Fig. 2. Expression of laminin- α 2 in CMD. Complete absence of the C-terminal portion of laminin- α 2 is associated with a more severe phenotype, while partial deficiency of laminin- α 2 leads to a milder phenotype.

2). Mutations that tend to interfere with the interaction of laminin- α 2 with its binding partners cause more severe phenotypes even if the protein is detectable in tissues [15].

Recent developments of animal models and patient studies have greatly advanced the understanding of disease mechanisms involved with MDC1A. The current animal models available to study are the *dy* and *dy*^{2J} mice (natural occurring mouse models with absent and reduced laminin- α 2 expression) and the genetically engineered models *dy*^W and *dy*^{3K} [43–46]. In patients with MDC1A and in the *dy/dy* mice, structural alterations of the basal lamina have been observed [47]. The integral structural organization of the basal lamina is crucial to the function of skeletal muscle, and the observed derangement would have expected implications on the growth, maintenance and force development in skeletal muscle. In *dy/dy*^{2J} mice, the distribution of laminin, dystroglycan and dystrophin were abnormal and not costameric. This represents a structural abnormality directly affecting the force generating capacity of the muscle and a possible explanation for the generalized muscle weakness [8]. The altered basal lamina morphology in Schwann cells is a possible cause of the slowed peripheral nerve conduction, and a likely contribution to the sequelae of this disease.

2.3. Therapy and future perspectives

Currently, there is no course of treatment that deals directly with laminin- α 2 deficiency in MDC1A patients, although possible treatments have been investigated. Expression of laminin- α 2 in *dy*^W and *dy*^{2J} mice (both partly deficient) causes some degree of rescue in the muscle phenotype with improved longevity and muscle morphology [48]. Overexpression of agrin in laminin- α 2 deficient mice has been shown to reduce the disease effects in muscle tissue by stabilizing α -dystroglycan which normally binds laminin [49–51]. Other molecular routes have been shown to benefit the phenotype of laminin- α 2 deficient mice. Transgenic overexpression of laminin- α 1 proves to be beneficial to the skeletal muscle and infertility phenotype of laminin- α 2 deficient mice [52,53]. Various studies demonstrated that increased apoptosis plays a role in the pathogenesis of laminin- α 2 deficient muscular dystrophy [31]. Inhibition of apoptosis has consequently been shown to ameliorate the skeletal muscle phenotype in Lama2-null mice [54,55]. Recent work investigated the mechanism by which the extraocular muscle (EOM) is spared from disease effects in *dy* mice.

Upregulation of laminin- α 4 in EOM subsequent to laminin- α 2 deficiency is thought to provide a protective function by binding integrins [56]. The possibility of laminin- α 4 as a protective agent opens up yet another avenue of research in the search for novel and effective therapeutic interventions.

2.4. Dystroglycanopathies (congenital disorders of O-glycosylation)

Within the last few years an increasing number of genes encoding for putative or demonstrated glycosyltransferases have been associated with various forms of autosomal recessive congenital muscular dystrophies often associated with structural eye and brain changes [57–59]. Six of these genes (*POMT1*, *POMT2*; *POMGnT1*; *FKRP*; *Fukutin*; *LARGE*) encode for proteins involved in the glycosylation of α -dystroglycan (Fig. 1b). Abnormal glycosylation of this molecule is a common finding in all the respective conditions (Walker–Warburg syndrome; Muscle–Eye–Brain disease; congenital muscular dystrophy type 1C; Fukuyama congenital muscular dystrophy and congenital muscular dystrophy type 1D). Despite that the defect of abnormal glycosylated dystroglycan expression appears to be secondary, its critical involvement in the pathogenesis of these muscular dystrophies led to the term dystroglycanopathies.

Dystroglycan is essential for basement membrane formation [60]. Generation of dystroglycan-null mice leads to embryonic lethality due to failure of basement (Reichert's) membrane formation that separates the embryo from the maternal circulation [61]. Generation of chimeric and skeletal muscle specific dystroglycan null mice (*MCK-null*) demonstrate loss of the dystrophin–glycoprotein complex with subsequent development of muscular dystrophy [62,63]. Interestingly, *MCK-null* mice do not develop progressive muscular dystrophy due to preserved dystroglycan expression in satellite cells and subsequent efficient muscle regeneration indicating that maintenance of effective muscle regeneration represents a key mechanism in the pathogenesis of muscular dystrophies [62].

Dystroglycan is encoded by the *DAG1* gene and undergoes posttranslational modification to yield two glycoproteins known as α - and β -dystroglycan [64]. Dystroglycan was originally isolated from skeletal muscle as an integral membrane component of the dystrophin–glycoprotein complex (DGC) [65]. At the sarcolemma β -dystroglycan binds intracellularly to dystrophin,

which binds to the actin cytoskeleton, and extracellularly to α -dystroglycan. α -Dystroglycan, a highly glycosylated peripheral membrane protein, completes the link from the cytoskeleton to the basal lamina by binding to extracellular matrix proteins containing LamG domains, such as laminin [66], neurexin [67], agrin [68,69], and perlecan [15]. Dystroglycan undergoes *N*-linked and extensive *O*-linked glycosylation, and as a result α -dystroglycan migrates on SDS-PAGE as a broad band with an approximate molecular mass of 120–180 kDa, depending on tissue type (156 kDa in muscle, predicted molecular mass is \sim 75 kDa) [70]. The perturbation of the synthesis of *O*-mannosyl tetrasaccharide (a fairly rare modification in mammals) leads to hypoglycosylation of α -dystroglycan and abolishes ligand-binding activity [64], [71]. It is believed that hypoglycosylation of α -dystroglycan and subsequent perturbation of dystroglycan binding to its ligand partners, in particular to laminin, leads to disruption of the critical link between the cytoskeleton and extracellular matrix in skeletal muscle. During the last few years it has become clear that hypoglycosylation of α -dystroglycan plays a crucial role in various forms of muscular dystrophies. Moreover, the severity of the phenotype and the degree of organ involvement can vary significantly (see below). It should be emphasized that immunohistochemical staining for the glycosylated form of α -dystroglycan serves as a straightforward tool in the diagnostic muscle biopsy workup of dystroglycanopathies irrespective of the specific gene mutation. The following paragraphs represent an overview of the different forms of muscular dystrophies caused by abnormal glycosylation of α -dystroglycan.

3. Congenital muscular dystrophy type 1D (MDC1D)

The identification of altered glycosylation of α -dystroglycan due to a loss-of-function mutation of a putative glycosyltransferase named *Large* in the myodystrophy mouse model (*Large*^{myd}) was the first demonstration that abnormal glycosylation can cause a neuromuscular disorder [71,72]. The *Large* gene encodes a putative glycosyltransferase with a transmembrane domain followed by a coiled-coil domain and two DxD-containing catalytic domains [58]. The *Large*^{myd} mouse develops muscular dystrophy, abnormal gait and posture and decreased reproductive fitness, cardiomyopathy, sensorineural hearing loss, neuronal migration defects and abnormal retinal transmission [71,73]. Longman and colleagues [74] recently identified a heterozygous mutation G1525A (Glu509Lys) in exon 13 and a heterozygous 1 bp insertion, 1999insT in exon 15 in the *LARGE* gene in a 17 year-old girl. The patient presented with congenital onset of weakness (around 5 months of age), profound mental retardation and an abnormal electroretinogram with significant alteration of the b-wave response. MRI of the brain revealed white matter changes and subtle structural abnormalities indicative of abnormal neuronal migration [74]. The skeletal muscle biopsy of this patient showed severe muscular dystrophy with reduced expression of glycosylated α -dystroglycan, and biochemical analysis revealed decreased molecular weight of α -dystroglycan and impaired laminin-binding activity.

LARGE exhibits important functions in skeletal muscle. Kanagawa et al. [75] demonstrated that molecular recognition by *LARGE* is essential in the biosynthetic pathway for a mature and functional dystroglycan [75] as post-translational modification of α -dystroglycan by *LARGE* occurs within the mucin-like domain. Biochemical evidence revealed that interaction of *LARGE* with the N-terminal domain of α -dystroglycan represents an intracellular enzyme recognition motif which is required to initiate efficient glycosylation. These data indicate that disruption of the dystroglycan-laminin linkage caused by absence of the critical glycosylation/*LARGE* recognition represents an essential mechanistic pathway ultimately leading to skeletal muscle cell necrosis and degeneration in muscular dystrophy [75]. There are currently no specific therapeutic alternatives available, however, Barresi et al. [76] showed that overexpression of *LARGE* in *Large*^{myd} mice induced synthesis of glycan-enriched α -dystroglycan accompanied by high affinity for extracellular ligands subsequently ameliorating the dystrophic pathology in these mice. Moreover, the authors demonstrated that overexpression of *LARGE* is able to bypass glycosylation defects in other forms of muscular dystrophies caused by abnormal glycosylation of dystroglycan. These data emphasize that manipulation of endogenous *LARGE* expression and activity represents a promising future therapeutic target for various muscular dystrophy syndromes caused by abnormal glycosylation of α -dystroglycan.

4. Walker–Warburg syndrome

Walker–Warburg syndrome (WWS) is the most severe amongst the dystroglycanopathies, with most patients dying by age of 3 years [77]. It is characterized by severe congenital muscular dystrophy, ocular abnormalities (such as retinal detachment and malformations, cataracts, microphthalmia, anterior and posterior chamber malformations, optic nerve hypoplasia, coloboma, glaucoma), and structural brain abnormalities (type II lissencephaly or cobblestone lissencephaly, agenesis of the corpus callosum, cerebellar hypoplasia, hydrocephalus and rarely encephalocele) [78]. The pathological changes in the central nervous system are thought to be secondary to pial glial limitans defects which resemble the morphological findings observed in mice with a tissue specific deletion of dystroglycan in brain [79].

Belran-Valero de Bernabe et al. [80] identified mutations in the gene encoding protein *O*-mannosyltransferase I (POMT1) in 6 out of 30 unrelated cases with WWS suggesting genetic heterogeneity. Subsequent to the discovery of the initial disease causing mutations various other forms of congenital muscular dystrophies have been associated with mutations in POMT1. The expanding phenotype of patients with POMT1 mutations includes microcephaly, calf hypertrophy [81] and patients who do not exhibit signs of ocular and brain malformations [82]. Moreover, mutations in POMT2, which together with POMT1 is required to achieve protein *O*-mannosyltransferase activity, has been demonstrated in patients with classic WWS [83].

POMT1, which belongs to the family of protein mannosyltransferases has three transmembrane segments in the C-

terminal. As it has no apparent Asp–Xaa–Asp motif, POMT1 differs markedly from the other glycosyltransferases and putative transferases and therefore might function outside of the Golgi apparatus. POMT1 and POMT2 are both ER-resident glycosyltransferases which act as a complex in catalyzing the O-mannosylation of α -dystroglycan [83].

Profound depletion of α -dystroglycan and defective glycosylation of α -dystroglycan causing loss of laminin-binding activity in skeletal muscle and peripheral nerve can be observed in patients with POMT1 mutations [80,84–86].

5. Muscle–eye–brain disease

Muscle–eye–brain disease (MEB) is an autosomal recessive disorder characterized by congenital muscular dystrophy, ocular abnormalities (congenital myopia, glaucoma and retinal hypoplasia), mental retardation and structural brain malformations (pachygyria, cerebellar hypoplasia and flat brain stem) [87]. Most of the patients so far have been described in a genetically isolated population, the Finns [77] although mutations have now been described throughout the world [88]. Yoshida et al. [89] identified a mutation in the gene that encodes O-linked mannose β 1,2-*N*-acetylglucosaminyl-transferase (POMGnT1), a type II membrane protein similar to other Golgi glycosyltransferases. Mutations of the POMGnT1 gene comprise the first biochemical evidence that congenital muscular dystrophies associated with loss of α -dystroglycan expression are indeed a defect of protein glycosylation, and enzyme activity of POMGnT1 has been found to be significantly reduced [89]. Hypoglycosylation of α -dystroglycan in skeletal muscle is associated with abolished ligand binding activity of laminin, agrin and neuroligin [71]. Mutations in the POMGnT1 gene have also been identified in patients outside of Finland [90], namely in Japan and Korea. Interestingly, genetic analyses revealed that patients with milder clinical cases most often exhibit a mutation located towards the 3' end of the POMGnT1 gene, while patients with a more severe phenotype tend to have mutations toward the 5' end of the gene [90].

Various groups have tried to develop enzymatic assays to diagnose POMGnT1 related conditions. Zhang et al. [91] used an enzymatic assay with commercially available reagents and demonstrated decreased POMGnT1 activity in skeletal muscle biopsies of four patients with POMGnT1 mutations. Vajsaar et al. [92], have recently reported a new fibroblast and lymphoblast based protein O-mannosyl β 1,2-*N*-acetylglucosaminyltransferase 1 enzymatic assay, which allows rapid and accurate diagnosis of carriers and patients with muscle–eye–brain type of congenital muscular dystrophy. Genetic engineering of mice lacking POMGnT1 reproduces the phenotype observed in patients and will be of benefit in studying further aspects of the molecular pathogenesis and the development of therapeutic strategies [93].

6. Fukuyama congenital muscular dystrophy

Fukuyama type congenital muscular dystrophy (FCMD) is an autosomal recessive disorder that is most often seen in

Japanese populations [94]. In Japan, its incidence is roughly 1 per 10,000 births, a frequency equivalent for Duchenne muscular dystrophy in the worldwide population. FCMD is characterized by severe congenital muscular dystrophy, cardiomyopathy, neuronal migration abnormalities associated with mental retardation and epilepsy, and frequently eye abnormalities (such as optic atrophy and retinal detachment) [94,95]. Most Japanese patients with the disease carry an ancestral 3 kB retrotransposon insertion in the 3' noncoding region of the *FCMD* gene [96], causing near absence of fukutin mRNA in lymphoblastic cells isolated from FCMD patients.

A broad correlation between genotype and phenotype in FCMD patients has been recognized. It appears that patients who are homozygous for the initially described ancestral mutation have a rather milder phenotype, while disease severity (associated eye abnormalities such as retinal detachment and microphthalmos) increases in patients who are compound heterozygous for the ancestral mutation and a more severe loss-of-function mutation [97]. Interestingly, in contrast to *fukutin*-null mice which are not viable, homozygous null mutations in the *FCMD* gene have recently been characterized in two patients of Turkish origin, suggesting that human life is compatible with a homozygous null mutation [98]. These patients presented with a more severe, WWS-like phenotype than the general FCMD patient population and had a substantial depletion of α -dystroglycan as shown by immunofluorescence. This was the first case of a fukutin mutation found outside the Japanese population.

Fukutin, the product of the *FCMD* gene, has sequence similarities to several putative glycosyltransferases and has an Asp–Xaa–Asp motif in its C-terminus. This motif is conserved in many families of glycosyltransferases and is essential for enzymatic activity [99]. Hayashi et al. [100], demonstrated that α -dystroglycan and laminin α 2 expression were reduced in FCMD patient's skeletal and cardiac muscle. Generation of chimeric mice for *fukutin* demonstrated muscular dystrophy with reduced survival rate, and a significant disorganization of the laminar structures of the cerebral and cerebellar cortices and the hippocampus [101]. These mice also exhibited defects in lens development and retinal detachment, as well as cortical neuronal over-migration and defects of the interhemispheric fissure. Biochemical analysis of these mice revealed decreased expression of glycosylated α -dystroglycan and disrupted laminin ligand activity. Further analyses of human and mouse models are needed to dissect the functional role of fukutin in muscle and nerve tissues.

7. Congenital Muscular Dystrophy Type 1C (MDC1C)

MDC1C is characterized by mutations in the fukutin-related protein gene (*FKRP*) was initially characterized based upon its sequence homology with fukutin [102]. Mutations in the *FKRP* gene can be detected in a very broad patient population. The two distinct phenotypes can be categorized into congenital muscular dystrophy type 1C (MDC1C) and limb girdle muscular dystrophy type 2I (LGMD 2I) (for review see [57–59]). The

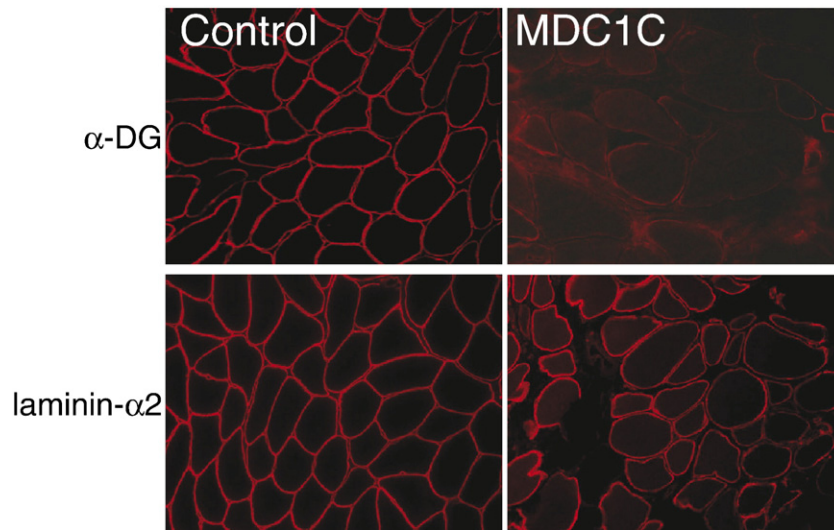


Fig. 3. Loss of glycosylated α -dystroglycan in a patient with a mutation in the *FKRP* gene. Note that in this patient, expression of laminin- α 2 is not affected.

main difference between these two disorders is that patients in the MDC1C category generally present with severe muscle weakness early in life and usually do not achieve ambulation. Recent reports of patients with *FKRP* mutations exhibit evidence of cerebellar abnormalities, lissencephaly, pachygyria and brain stem hypoplasia [103,104]. Immunohistochemical studies of α -dystroglycan in skeletal muscle of MDC1C muscle suggest a correlation of α -dystroglycan expression and disease severity [105]. Patients with MDC1C and a phenotype at the severe end of the disease spectrum showed profound depletion of α -dystroglycan expression (Fig. 3). In contrast, patients with LGMD2I and a milder phenotype have more variable and subtle alterations in α -dystroglycan labeling [105].

Patients with MDC1C often are compound heterozygous for either one missense and one nonsense or two missense mutations, while patients with two nonsense mutations have not yet been described [106]. Another evidence of clinical and molecular heterogeneity has come from reports of novel missense mutations in the *FKRP* gene which causes marked phenotypic variability within the same family [107,108]. These observations suggest that genetic modifiers and/or environmental factors play a role in modulating disease severity in MDC1C and LGMD2I.

FKRP, a type II transmembrane protein, is ubiquitously expressed in all tissues. It contains a DxD motif suggestive of a glycosyltransferase. In vitro localization studies have shown a subcellular localization within the Golgi apparatus and disease causing mutations lead to endoplasmic reticulum retention of the mutated protein [109,110]. Interestingly, overexpression in Chinese hamster ovary cells revealed that *FKRP* directly affects dystroglycan processing, a phenomenon completely abolished in case of a mutated *FKRP* [109,110].

8. Ullrich congenital muscular dystrophy (UCMD)

UCMD (MIM #254090) is an autosomal recessive disorder which has been initially characterized by its clinical manifesta-

tions of generalized hypotonia and contractures [111]. UCMD, as well as the phenotypically less severe Bethlem Myopathy, results from a deficiency in the extracellular matrix protein Collagen VI [3]. Collagen VI comprises the α 1, α 2, and α 3 peptide chains which are encoded by the corresponding genes *COL6A1*, *COL6A2*, and *COL6A3*. Mutations in *COL6A1* and *COL6A2* (located at 21q22), and *COL6A3* (at 2q37) cause UCMD, and both recessive and dominant patterns are observed as modes of inheritance [112–115]. Collagen VI is a microfibrillar component found throughout the extracellular matrix of fibroblasts and the connective tissue of skin, large vessels, as well as skeletal, smooth and cardiac muscle [116,117]. Its prevalence in the reticular layer of the basement membrane, and its binding to fibronectin and collagen type IV [43], indicates a structural role in muscle fibers. The lost connection between the basal lamina and interstitium, as a result of deficient collagen VI, has been implicated in the pathogenesis associated with UCMD [118]. Collagen VI has also been shown to induce proliferation of fibroblasts [119], drive gene expression, enhance tyrosine kinase activity [120], and inhibits Bax activation consequently reducing cellular apoptosis events [121]. The disruption of these functions represents potential components of UCMD pathogenesis and provides direction for the discovery of therapeutic measures.

8.1. Clinical manifestations and diagnosis

Patients with UCMD present in the neonatal period with hypotonia, distal joint laxity, and proximal contractures. Hip dislocation and torticollis are common features evident during the first year of life along with scoliosis, severe respiratory impairment, spinal rigidity, and failure to thrive [122]. Severity of clinical features is highly variable and closely linked to the degree of collagen deficiency [123]. For example, a subset of patients achieves ambulation and suffers a relatively mild motor deficiency while others have severely impaired motor function and development. Respiratory complications can

advance resulting in the need for ventilatory support, and contractures can worsen over time often requiring surgical intervention. Hyperhidrosis of the skin, facial weakness with high arch palate, and prominent ears are common features of patients with UCMD [3]. Creatine kinase levels are normal or within five times the normal level, and mental development is unaffected [3]. Diagnosis requires muscle biopsy with immunohistochemical analysis of collagen VI in tissue and cultured fibroblasts and gene testing. Histological abnormalities of skeletal muscle in UCMD include variation in fiber size, muscle fiber necrosis and increased connective tissue in the endomysium and perimysium. Immunohistochemical staining can reveal a variety of patterns ranging from complete absence in some patients, to partial reduction in others, and some cases with no apparent reduction in collagen VI level [118,122]. Other samples have been identified where collagen VI fails to localize to the basement membrane surrounding the muscle fiber causing a mild form of UCMD [114]. Collagen VI may also fail to form the normal network structure in the extracellular matrix due to truncated or absent α chains [124]. Muscle MRI has also been proposed as a diagnostic tool, specifically when collagen VI expression is normal in skeletal muscle and/or skin [125]. Patients with UCMD show diffuse patches of abnormal signal in the thigh muscles and display the pattern regardless of the level of collagen expression [125]. The genetic heterogeneity of this disorder introduces difficulties in molecular testing. Only a portion of the known cases have either collagen VI deficiency or mutations in the genes coding for collagen VI α chains, but mutations in each of the three genes have been characterized and could potentially be used for genetic testing. Prenatal diagnosis, through CVS, is possible in families where an affected child displays UCMD with collagen VI deficiency and a distinguishable genotype. Brockington et al. [126], have recently reported haplotype analysis of markers on COL6A3, in conjunction with immunohistochemical collagen VI labeling as a measure to diagnose UCMD in a fetus.

8.2. Pathogenesis and genetics

Upon discovery of the first mutations in the collagen VI genes, it was established that UCMD displayed recessive inheritance through homozygous or compound heterozygous mutations. Patients can present with recessive mutations in both COL6A2 and COL6A3 that caused a deficiency in collagen VI and the UCMD phenotype [112–115]. Dominant mutations in the same COL6A genes are associated with the less severe Bethlem Myopathy. Later it was discovered that a heterozygous deletion in COL6A1 is responsible for the more severe UCMD phenotype [114]. This exposed the first dominant inheritance pattern for UCMD, blurring the lines between Bethlem Myopathy and UCMD, and introducing new molecular mechanisms for the disorder [127]. Recently 79 Patients with Bethlem Myopathy and UCMD had all three COL6A genes sequenced and examined. Many new mutations were discovered with 62% of patients showing possible mutations in at least one COL6A gene [128]. The severity of the disease follows

closely with the level of collagen VI deficiency [123], but loss of collagen VI may affect the level of disease through several mechanisms. EM images of a patient with complete collagen VI deficiency displayed the absence of microfibrils thereby disrupting the link between the basal lamina and the interstitium. The loss of this connection has been implicated as a possible mechanism for the reduced structural integrity of muscle fibers in these patients [118]. EM also revealed changes in the ultrastructure of skin biopsies. Collagen fibrils showed variation in size and ground substance, findings that are also features of connective tissue disorders such as Ehlers–Danlos syndromes [129]. Experiments with collagen VI deficient mice have enhanced our understanding of other possible pathomechanisms in UCMD [130]. Muscle fibers in these mice showed alterations in sarcoplasmic reticular ultrastructure associated with mitochondrial dysfunction and increased apoptosis. The observed ultrastructural and physiologic changes caused a measurable loss of contractile strength. Administration of cyclosporine A reduced the apoptotic events and led to preservation of structural integrity of skeletal muscle fibers [131]. A recent study by Usuki et al. [132] demonstrated yet another possibility for pathogenetic mechanism and therapeutic intervention. The authors described that nonsense mediated decay (NMD) may be responsible for some of the collagen mutations in patients with UCMD. They were able to show that siRNA-mediated knockdown of SMG-1 or Upf1 (both essential proteins of NMD) led to up-regulation of the mutant triple-helical collagen VI, resulting in the formation of partially functional extracellular matrix.

8.3. Therapy and future perspectives

Currently there is no direct treatment for deficiency of Collagen VI, but therapeutic intervention to prevent the sequelae of UCMD is important for the ongoing health and quality of life of the patients. Contractures, respiratory failure, scoliosis, and recurrent infections are common, and measures such as early mobilization, surgical correction, respiratory assistance, and early or preventative treatment of infections are required to provide patients with maximum health, mobility and functionality [128].

9. RSMD1 and selenocysteine

Rigid spine muscular dystrophy or RSMD1 is a rare form of autosomal recessive congenital muscular dystrophy caused by mutations in the SEPNI gene [133–135]. The SEPNI gene encodes for selenoprotein N which is a selenium containing glycoprotein located within the endoplasmic reticulum [135]. Selenium is added to the peptide chain in the form of a single selenocysteine residue by a distinctly recognized stop codon. Several other selenoproteins have been characterized, many of which are enzymes involved in oxidation–reduction reactions, and all of which have selenocysteine at their active site. Full-length SEPNI transcripts are expressed in a variety of tissues including skeletal muscle, brain, and lung. It is also found in the placenta and is more prevalent in fetal tissue than adult

[134,135]. Recently, the spectrum of neuromuscular disorders caused by mutations in the selenoprotein N has been broadened. Ferreiro et al. [136], demonstrated mutations in the SEPNI gene in patients with classical presentation of multi-minicore disease. In addition, desmin-related myopathy with Mallory body-like inclusions is caused by mutations in the SEPNI gene [137].

9.1. Clinical manifestations and diagnosis

RSMD1 presents in the neonatal period with contractures of the spinal extensors leading to rigidity of spine and thoracic cage, facial and neck weakness, and hypotonia predominately found in the axial musculature [138]. In infancy, patients develop thoracolumbar scoliosis and diaphragmatic weakness often requiring ventilation. Delay of gross motor milestones is evident, although ambulation is eventually achieved and preserved in most patients. Due to palatal weakness, nasal speech is common. Patients exhibit failure to thrive with muscle wasting. Patients do not exhibit mental retardation and have normal brain MRIs. Muscular hypertrophy and contractures are not associated with this condition, and serum creatine kinase is close to or within the normal range.

Skeletal muscle biopsies show non-specific myopathic changes such as fiber diameter variability, prevalence of type 1 fibers, atrophy and internalization of nuclei. Some specimens contain minicores typical of classical minicore myopathies [136]. Antibodies directed against the 70-kDa SEPNI can show absence of the protein in fibroblasts of patients with nonsense mutations. Screening for mutations in the SEPNI gene is required to establish the diagnosis of RSMD1.

9.2. Pathogenesis and genetics

Identification of selenoproteins as a cause for muscular dystrophies is highly novel, therefore little is known about the function of these proteins in skeletal muscle. Okamoto et al. [139], recently described two new SEPNI mutations in two Japanese patients with RSMD1. Immunohistochemical studies in these patients showed a reduced and irregular expression of selenoprotein N and calnexin, a transmembrane protein of the endoplasmic reticulum. One of the families studied showed a homozygous 20-base duplication mutation at 80 (80_99dup, frameshift at R27) which should lead to significant nonsense-mediated decay (NMD). Unexpectedly, the authors detected a truncated selenoprotein N suggesting that SEPNI mRNAs may be resistant to NMD. Further evaluation of NMD and other potential pathways in this disorder is needed to shed more light into the mechanism of selenoprotein related muscle diseases.

9.3. Therapy and future perspectives

Possible therapies have been elusive due to the unique nature of RSMD1. Unlike other congenital muscular dystrophies it does not affect the basal lamina or laminin receptors. Novel

pathways will need to be explored as further work helps define the nature of this disease and its pathology.

10. $\alpha 7$ Integrin

The $\alpha 7\beta 1$ integrin is a laminin receptor found on the surface of myocytes forming an important connection between the cell surface and basal lamina. Both α and β subunits are expressed in tissue-specific variants formed by differential splicing in a developmentally dependent manner [140,141]. The $\alpha 7A$ and $\alpha 7\beta$ variants are expressed to a large extent in skeletal muscle, specifically the myotendinous junctions, neuromuscular junctions, and the sarcolemma, although it is also found in cardiac and smooth muscle [142,143]. Alpha7B integrin binds laminin within the plasma membrane forming an important support of structural and functional stability within the skeletal muscle [26,31]. The $\alpha 7\beta 1$ integrin also functions to mediate migration and proliferation of myoblasts [140]. More recently, the functional understanding of $\alpha 7\beta 1$ has been extended to the development and maintenance of vascular smooth muscle [144]. The discovery of the ITGA7 gene at locus 12q13 and the subsequent generation of a homozygous knockout mouse model were key steps in the determination of functional deficiencies created in the absence of $\alpha 7$ integrin [143,145]. Among these were clear changes in skeletal muscle indicative of muscular dystrophy, findings that were echoed later in patients with congenital myopathy and reduced expression of $\alpha 7$ integrin [MIM 600536, [146]].

10.1. Clinical manifestations and diagnosis

Three patients have been characterized with a deficiency in $\alpha 7$ integrin leading to an autosomal recessive form of congenital myopathy [146]. One patient showed significant developmental delay characterized by mental retardation and impaired achievement of motor milestones. There was also a subtle increase in serum creatine kinase. A second patient was observed to have similar motor delay, although eventually achieved ambulation at 2 years of age. This patient was not found to have mental involvement, but surgery was required to repair torticollis and hip dislocation at 2 months of age, and creatine kinase levels were found to be mildly elevated. A third patient displayed torticollis and hypotonia, but had no apparent mental involvement [146].

10.2. Pathogenesis and genetics

Two of the patients were compound heterozygous for mutated alleles in the ITGA7 gene. Both patients had an allele containing a 98-bp deletion, but the complimentary alleles were unique in both cases. The third patient had a reduction in ITGA7 mRNA with no observed mutation in the ITGA7 gene. Congenital myopathy and deficiency of $\alpha 7$ integrin is evident in all of these patients by immunocytochemical techniques. They are differentiated by the normal expression of laminin- $\alpha 2$, and at least one patient has shown variable fiber size and adipose infiltration [146].

10.3. Therapy and future perspectives

Currently there are no treatments available that can restore the level of functioning $\alpha 7\beta 1$, however, the potential for replacing $\alpha 7$ integrin in other forms of muscular dystrophy have recently been investigated. It was found that mice lacking dystrophin and utrophin had lower prevalence of muscle disease, better mobility, and longer lives when bred with mice overexpressing $\alpha 7\beta 1$ integrin [147]. Integrin $\alpha 7\beta 1$ and the dystroglycan complex are the major laminin receptors in the myocyte membrane, and the expression of $\alpha 7\beta 1$ is observed to maintain the integrity of the myotendinous and neuromuscular junction normally lost in dystrophin/utrophin deficient mice [147,148]. These findings are supported by demonstration that lack of $\alpha 7$ integrin and dystrophin exacerbates the dystrophic disease process of dystrophin-deficient *mdx* mice [149].

11. Conclusion

The last century of research in the field of congenital muscular dystrophies has led to exciting new discoveries regarding the pathogenesis of these disorders. It has not only significantly enhanced our understanding of the pathogenesis of skeletal muscle pathology but shed light into the mechanisms of neuronal migration defects. For many years congenital muscular dystrophies were thought to be a group of disorders linked to abnormalities and perturbation of the extracellular matrix. The identification of mutations encoding for selenoproteins in rigid spine syndrome which are enzymes located in the endoplasmic reticulum, has led to a completely new avenues of research in the pathogenesis of congenital muscular dystrophies and potentially other muscle disorders. Further characterization of the existing pathways and their potential interaction with each other as well as identification of novel clinical and molecular entities will expand our current knowledge and serve as the basis for the development of future therapeutic strategies. Among various options, these may potentially involve enzymatic modifications of the glycosylation process of α -dystroglycan as well as modification of the oxidation–reduction reactions involving selenoproteins.

References

- [1] F. Batten, Three cases of myopathy, infantile type, *Brain* 26 (1903) 147–148.
- [2] T. Voit, F. Tome, The congenital muscular dystrophy, *Myolog*, Engel., A (2004).
- [3] C. Jimenez-Mallebrera, S.C. Brown, C.A. Sewry, F. Muntoni, Congenital muscular dystrophy: molecular and cellular aspects, *Cell. Mol. Life Sci.* 62 (2005) 809–823.
- [4] F. Muntoni, T. Voit, The congenital muscular dystrophies in 2004: a century of exciting progress, *Neuromuscul. Disord.* 10 (2004) 635–649.
- [5] A. Helbling-Leclerc, X. Zhang, H. Topaloglu, C. Cruaud, F. Tesson, J. Weissenbach, F.M. Tome, K. Schwartz, M. Fardeau, K. Tryggvason, et al., Mutations in the laminin alpha 2-chain gene (LAMA2) cause merosin-deficient congenital muscular dystrophy, *Nat. Genet.* 11 (1995) 216–218.
- [6] F.M. Tome, T. Evangelista, A. Leclerc, Y. Sunada, E. Manole, B. Estournet, A. Barois, K.P. Campbell, M. Fardeau, Congenital muscular dystrophy with merosin deficiency, *C. R. Acad. Sci., III* 317 (1994) 351–357.
- [7] H. Colognato, P.D. Yurchenco, Form and function: the laminin family of heterotrimers, *Dev. Dyn.* 218 (2000) 213–234.
- [8] P.D. Yurchenco, Y.S. Cheng, K. Campbell, S. Li, Loss of basement membrane, receptor and cytoskeletal lattices in a laminin-deficient muscular dystrophy, *J. Cell. Sci.* 117 (2004) 735–742.
- [9] D. Hillaire, A. Leclerc, S. Faure, H. Topaloglu, N. Chiannikulchai, P. Guicheney, L. Grinas, P. Legos, J. Philpot, T. Evangelista, et al., Localization of merosin-negative congenital muscular dystrophy to chromosome 6q2 by homozygosity mapping, *Hum. Mol. Genet.* 9 (1994) 1657–1661.
- [10] K. Ehrig, I. Leivo, W.S. Argraves, E. Ruoslahti, E. Engvall, Merosin, a tissue-specific basement membrane protein, is a laminin-like protein, *Proc. Natl. Acad. Sci. U. S. A.* 87 (1990) 3264–3268.
- [11] R. Vuolteenaho, M. Nissinen, K. Sainio, M. Byers, R. Eddy, H. Hirvonen, T.B. Shows, H. Sariola, E. Engvall, K. Tryggvason, Human laminin M chain (merosin): complete primary structure, chromosomal assignment, and expression of the M and A chain in human fetal tissues, *J. Cell Biol.* 124 (1994) 381–394.
- [12] X. Zhang, R. Vuolteenaho, K. Tryggvason, Structure of the human laminin alpha2-chain gene (LAMA2), which is affected in congenital muscular dystrophy, *J. Biol. Chem.* 271 (1996) 27664–27669.
- [13] B.L. Patton, J.H. Miner, A.Y. Chiu, J.R. Sanes, Distribution and function of laminins in the neuromuscular system of developing, adult, and mutant mice, *J. Cell Biol.* 139 (1997) 1507–1521.
- [14] C.A. Sewry, The role of immunocytochemistry in congenital myopathies, *Neuromuscul. Disord.* 6 (1998) 394–400.
- [15] J.F. Talts, Z. Andac, W. Gohring, A. Brancaccio, R. Timpl, Binding of the G domains of laminin alpha1 and alpha2 chains and perlecan to heparin, sulfatides, alpha-dystroglycan and several extracellular matrix proteins, *EMBO J.* 18 (1999) 863–870.
- [16] M.D. Henry, J.S. Satz, C. Brakebusch, M. Costell, E. Gustafsson, R. Fassler, K.P. Campbell, Distinct roles for dystroglycan, beta1 integrin and perlecan in cell surface laminin organization, *J. Cell. Sci.* 114 (2001) 1137–1144.
- [17] Y.K. Hayashi, R. Koga, T. Tsukahara, H. Ishii, T. Matsuishi, Y. Yamashita, I. Nonaka, K. Arahata, Deficiency of laminin alpha 2-chain mRNA in muscle in a patient with merosin-negative congenital muscular dystrophy, *Muscle Nerve* (1995) 1027–1030.
- [18] E. Pegoraro, M. Fanin, C.P. Trevisan, C. Angelini, E.P. Hoffman, A novel laminin alpha2 isoform in severe laminin alpha2 deficient congenital muscular dystrophy, *Neurology* 55 (2000) 1128–1134.
- [19] C.C. Leite, L.T. Lucato, M.G. Martin, L.G. Ferreira, M.B. Resende, M.S. Carvalho, S.K. Marie, J.R. Jinks, U.C. Reed, Merosin-deficient congenital muscular dystrophy (CMD): a study of 25 Brazilian patients using MRI, *Pediatr. Radiol.* 35 (2005) 572–579.
- [20] J. Philpot, F. Cowan, J. Pennock, C. Sewry, V. Dubowitz, G. Bydder, F. Muntoni, Merosin-deficient congenital muscular dystrophy: the spectrum of brain involvement on magnetic resonance imaging, *Neuromuscul. Disord.* 9 (1999) 81–85.
- [21] A.L. Taratuto, F. Lubieniecki, D. Diaz, M. Schultz, V. Ruggieri, M. Saccoliti, A. Dubrovsky, Merosin-deficient congenital muscular dystrophy associated with abnormal cerebral cortical gyration: an autopsy study, *Neuromuscul. Disord.* 9 (1999) 86–94.
- [22] H.J. Gilhuis, H.J. ten Donkelaar, R.B. Tanke, D.M. Vingerhoets, M.J. Zwarts, A. Verrips, F.J. Gabreels, Nonmuscular involvement in merosin-negative congenital muscular dystrophy, *Pediatr. Neurol.* 26 (2002) 30–36.
- [23] N. Spyrou, J. Philpot, R. Foale, P.G. Camici, F. Muntoni, Evidence of left ventricular dysfunction in children with merosin-deficient congenital muscular dystrophy, *Am. Heart J.* 136 (1998) 474–476.
- [24] E. Mercuri, L. Dubowitz, A. Berardinelli, J. Pennock, M. Jongmans, S. Henderson, F. Muntoni, C. Sewry, J. Philpot, V. Dubowitz, Minor neurological and perceptuo-motor deficits in children with congenital muscular dystrophy: correlation with brain MRI changes, *Neuropediatrics* (1995) 156–162.
- [25] J. Philpot, F. Muntoni, Limitation of eye movement in merosin-deficient congenital muscular dystrophy, *Lancet* 353 (1999) 297–298.

- [26] R.D. Cohn, R. Herrmann, L. Sorokin, U.M. Wewer, T. Voit, Laminin alpha2 chain-deficient congenital muscular dystrophy: variable epitope expression in severe and mild cases, *Neurology* 51 (1998) 94–100.
- [27] C.A. Sewry, I. Naom, M. D'Alessandro, L. Sorokin, S. Bruno, L.A. Wilson, V. Dubowitz, F. Muntoni, Variable clinical phenotype in merosin-deficient congenital muscular dystrophy associated with differential immunolabelling of two fragments of the laminin alpha 2 chain, *Neuromuscul. Disord.* 7 (1998) 169–175.
- [28] R.D. Cohn, R. Herrmann, U.M. Wewer, T. Voit, Changes of laminin beta 2 chain expression in congenital muscular dystrophy, *Neuromuscul. Disord.* 6–7 (1997) 373.
- [29] R.D. Cohn, U. Mayer, G. Saher, R. Herrmann, A. van der Flier, A. Sonnenberg, L. Sorokin, T. Voit, Secondary reduction of alpha7B integrin in laminin alpha2 deficient congenital muscular dystrophy supports an additional transmembrane link in skeletal muscle, *J. Neurol. Sci.* 163 (1999) 140–152.
- [30] B.L. Patton, A.M. Connolly, P.T. Martin, J.M. Cunningham, S. Mehta, A. Pestronk, J.H. Miner, J.R. Sanes, Distribution of ten laminin chains in dystrophic and regenerating muscles, *Neuromuscul. Disord.* 6–7 (1999) 423–433.
- [31] P.H. Vachon, H. Xu, L. Liu, F. Loechel, Y. Hayashi, K. Arahata, J.C. Reed, U.M. Wewer, E. Engvall, Integrins (alpha7beta1) in muscle function and survival. Disrupted expression in merosin-deficient congenital muscular dystrophy, *J. Clin. Invest.* 100 (1997) 1870–1881.
- [32] C.A. Sewry, M. D'Alessandro, L.A. Wilson, L.M. Sorokin, I. Naom, S. Bruno, A. Ferlini, V. Dubowitz, F. Muntoni, Expression of laminin chains in skin in merosin-deficient congenital muscular dystrophy, *Neuropediatrics* 28 (1998) 217–222.
- [33] I. Naom, M. D'Alessandro, C. Sewry, A. Ferlini, H. Topaloglu, A. Helbling-Leclerc, P. Guicheney, K. Schwartz, Z. Akcoren, V. Dubowitz, F. Muntoni, The role of immunocytochemistry and linkage analysis in the prenatal diagnosis of merosin-deficient congenital muscular dystrophy, *Hum. Genet.* 99 (1997) 535–540.
- [34] I. Naom, C. Sewry, M. D'Alessandro, H. Topaloglu, A. Ferlini, L. Wilson, V. Dubowitz, F. Muntoni, Prenatal diagnosis in merosin-deficient congenital muscular dystrophy, *Neuromuscul. Disord.* 7 (1997) 176–179.
- [35] M. Vainzof, P. Richard, R. Herrmann, C. Jimenez-Mallebrera, B. Talim, L.U. Yamamoto, C. Ledeuil, R. Mein, S. Abbs, M. Brockington, N.B. Romero, M. Zatz, H. Topaloglu, T. Voit, C. Sewry, F. Muntoni, P. Guicheney, F.M. Tome, Prenatal diagnosis in laminin alpha2 chain (merosin)-deficient congenital muscular dystrophy: a collective experience of five international centers, *Neuromuscul. Disord.* 9–10 (2005) 588–594.
- [36] T. Voit, M. Fardeau, F.M. Tome, Prenatal detection of merosin expression in human placenta, *Neuropediatrics* 25 (1994) 332–333.
- [37] M. Korhonen, I. Virtanen, Immunohistochemical localization of laminin and fibronectin isoforms in human placental villi, *J. Histochem. Cytochem.* (2001) 313–322.
- [38] M. Brockington, C.A. Sewry, R. Herrmann, I. Naom, A. Dearlove, M. Rhodes, H. Topaloglu, V. Dubowitz, T. Voit, F. Muntoni, Assignment of a form of congenital muscular dystrophy with secondary merosin deficiency to chromosome 1q42, *Am. J. Hum. Genet.* 66 (2000) 428–435.
- [39] Z. Tezak, P. Prandini, M. Boscaro, A. Marin, J. Devaney, M. Marino, M. Fanin, C.P. Trevisan, J. Park, W. Tyson, R. Finkel, C. Garcia, C. Angelini, E.P. Hoffman, E. Pegoraro, Clinical and molecular study in congenital muscular dystrophy with partial laminin alpha 2 (LAMA2) deficiency, *Human Mutat.* 21 (2003) 103–111.
- [40] M. Nissinen, A. Helbling-Leclerc, X. Zhang, T. Evangelista, H. Topaloglu, C. Cruaud, J. Weissenbach, M. Fardeau, F.M. Tome, K. Schwartz, K. Tryggvason, P. Guicheney, Substitution of a conserved cysteine-996 in a cysteine-rich motif of the laminin alpha2-chain in congenital muscular dystrophy with partial deficiency of the protein, *Am. J. Hum. Genet.* 58 (1996) 1177–1184.
- [41] V. Allamand, Y. Sunada, M.A. Salih, V. Straub, C.O. Ozo, M.H. Al-Turaiqi, M. Akbar, T. Kolo, H. Colognato, X. Zhang, L.M. Sorokin, P.D. Yurchenco, K. Tryggvason, K.P. Campbell, Mild congenital muscular dystrophy in two patients with an internally deleted laminin alpha2-chain, *Hum. Mol. Genet.* 6 (1997) 747–752.
- [42] L.T. Guo, X.U. Zhang, W. Kuang, H. Xu, L.A. Liu, J.T. Vilquin, Y. Miyagoe-Suzuki, S. Takeda, M.A. Ruegg, U.M. Wewer, E. Engvall, Laminin alpha2 deficiency and muscular dystrophy; genotype-phenotype correlation in mutant mice, *Neuromuscul. Disord.* 13 (2003) 207–215.
- [43] H.J. Kuo, C.L. Maslen, D.R. Keene, R.W. Glanville, Type VI collagen anchors endothelial basement membranes by interacting with type IV collagen, *J. Biol. Chem.* 272 (1997) 26522–26529.
- [44] Y. Miyagoe, K. Hanaoka, I. Nonaka, M. Hayasaka, Y. Nabeshima, K. Arahata, Y. Nabeshima, S. Takeda, Laminin alpha2 chain-null mutant mice by targeted disruption of the Lama2 gene: a new model of merosin (laminin 2)-deficient congenital muscular dystrophy, *FEBS Lett.* 415 (1997) 33–39.
- [45] Y. Sunada, S.M. Bernier, A. Utani, Y. Yamada, K.P. Campbell, Identification of a novel mutant transcript of laminin alpha 2 chain gene responsible for muscular dystrophy and dysmyelination in dy2J mice, *Hum. Mol. Genet.* 4 (1995) 1055–1061.
- [46] H. Xu, X.R. Wu, U.M. Wewer, E. Engvall, Murine muscular dystrophy caused by a mutation in the laminin alpha 2 (Lama2) gene, *Nat. Genet.* 8 (1994) 297–302.
- [47] C. Minetti, M. Bado, G. Morreale, M. Pedemonte, G. Cordone, Disruption of muscle basal lamina in congenital muscular dystrophy with merosin deficiency, *Neurology* 46 (1996) 1354–1358.
- [48] W. Kuang, H. Xu, P.H. Vachon, L. Liu, F. Loechel, U.M. Wewer, E. Engvall, Merosin-deficient congenital muscular dystrophy. Partial genetic correction in two mouse models, *J. Clin. Invest.* 102 (1998) 844–852.
- [49] C.F. Bentzinger, P. Barzaghi, S. Lin, M.A. Ruegg, Overexpression of mini-agrin in skeletal muscle increases muscle integrity and regenerative capacity in laminin-alpha2-deficient mice, *FASEB J.* 19 (2005) 934–942.
- [50] J. Moll, P. Barzaghi, S. Lin, G. Bezakova, H. Lochmuller, E. Engvall, U. Muller, M.A. Ruegg, An agrin minigene rescues dystrophic symptoms in a mouse model for congenital muscular dystrophy, *Nature* 413 (2001) 302–307.
- [51] C. Qiao, J. Li, T. Zhu, R. Draviam, S. Watkins, X. Ye, C. Chen, J. Li, X. Xiao, Amelioration of laminin-alpha2-deficient congenital muscular dystrophy by somatic gene transfer of miniagrin, *Proc. Natl. Acad. Sci. U. S. A.* 102 (2005) 11999–12004.
- [52] K. Gawlik, Y. Miyagoe-Suzuki, P. Ekblom, S. Takeda, M. Durbeej, Laminin alpha1 chain reduces muscular dystrophy in laminin alpha2 chain deficient mice, *Hum. Mol. Genet.* 13 (2004) 1775–1784.
- [53] M. Hager, K. Gawlik, A. Nystrom, T. Sasaki, M. Durbeej, Laminin {alpha}1 chain corrects male infertility caused by absence of laminin {alpha}2 chain, *Am. J. Pathol.* 167 (2005) 822–833.
- [54] J.A. Dominov, A.J. Kravetz, M. Ardel, C.A. Kostek, M.L. Beermann, J.B. Miller, Muscle-specific BCL2 expression ameliorates muscle disease in laminin {alpha}2-deficient, but not in dystrophin-deficient, mice, *Hum. Mol. Genet.* 14 (2005) 1029–1040.
- [55] M. Girgenrath, J.A. Dominov, C.A. Kostek, J.B. Miller, Inhibition of apoptosis improves outcome in a model of congenital muscular dystrophy, *J. Clin. Invest.* 114 (2004) 1635–1639.
- [56] A. Nystrom, J. Holmblad, F. Pedrosa-Domellof, T. Sasaki, M. Durbeej, Extraocular muscle is spared upon complete laminin alpha2 chain deficiency: Comparative expression of laminin and integrin isoforms, *Matrix Biol.* (2006) (2006) [Epub ahead of print].
- [57] R.D. Cohn, Dystroglycan: important player in skeletal muscle and beyond, *Neuromuscul. Disord.* 15 (2005) 207–217.
- [58] P.T. Martin, The dystroglycanopathies: the new disorders of O-linked glycosylation, *Semin. Pediatr. Neurol.* 12 (2005) 152–158.
- [59] F. Muntoni, Journey into muscular dystrophies caused by abnormal glycosylation, *Acta Myol.* 23 (2004) 79–84.
- [60] M.D. Henry, K.P. Campbell, A role for dystroglycan in basement membrane assembly, *Cell* 95 (1998) 859–870.
- [61] R.A. Williamson, M.D. Henry, K.J. Daniels, R.F. Hrstka, J.C. Lee, Y. Sunada, O. Ibraghimov-Beskrovnya, K.P. Campbell, Dystroglycan is essential for early embryonic development: disruption of Reichert's membrane in Dag1-null mice, *Hum. Mol. Genet.* 6 (1997) 831–841.

- [62] R.D. Cohn, M.D. Henry, D.E. Michele, R. Barresi, F. Saito, S.A. Moore, J.D. Flanagan, M.W. Skwarchuk, M.E. Robbins, J.R. Mendell, R.A. Williamson, K.P. Campbell, Disruption of DAG1 in differentiated skeletal muscle reveals a role for dystroglycan in muscle regeneration, *Cell* 110 (2002) 639–648.
- [63] P.D. Cote, H. Moukhles, M. Lindenbaum, S. Carbonetto, Chimaeric mice deficient in dystroglycans develop muscular dystrophy and have disrupted myoneural synapses, *Nat. Genet.* 23 (1999) 338–342.
- [64] R. Barresi, K.P. Campbell, Dystroglycan: from biosynthesis to pathogenesis of human disease, *J. Cell. Sci.* 119 (2006) 199–207.
- [65] J.M. Ervasti, K. Ohlendieck, S.D. Kahl, M.G. Gaver, K.P. Campbell, Deficiency of a glycoprotein component of the dystrophin complex in dystrophic muscle, *Nature* 345 (1990) 315–319.
- [66] J.M. Ervasti, K.P. Campbell, A role for the dystrophin–glycoprotein complex as a transmembrane linker between laminin and actin, *J. Cell Biol.* (1993) 809–823.
- [67] S. Sugita, F. Saito, J. Tang, J. Satz, K.P. Campbell, T.C. Sudhof, A stoichiometric complex of neuroligins and dystroglycan in brain, *J. Cell Biol.* 154 (2001) 435–445.
- [68] J.T. Campanelli, S.L. Roberds, K.P. Campbell, R.H. Scheller, A role for dystrophin-associated glycoproteins and utrophin in agrin-induced AChR clustering, *Cell* 77 (1994) 633–674.
- [69] S.H. Gee, F. Montanaro, M.H. Lindenbaum, S. Carbonetto, Dystroglycan- α , a dystrophin-associated glycoprotein, is a functional agrin receptor, *Cell* 77 (1994) 675–686.
- [70] O. Ibraghimov-Beskrovnaia, J.M. Ervasti, C.J. Leveille, C.A. Slaughter, S.W. Sernett, K.P. Campbell, Primary structure of dystrophin-associated glycoproteins linking dystrophin to the extracellular matrix, *Nature* 355 (1992) 696–702.
- [71] D.E. Michele, R. Barresi, M. Kanagawa, F. Saito, R.D. Cohn, J.S. Satz, J. Dollar, I. Nishino, R.I. Kelley, H. Somer, V. Straub, K.D. Mathews, S.A. Moore, K.P. Campbell, Post-translational disruption of dystroglycan–ligand interactions in congenital muscular dystrophies, *Nature* 418 (2002) 417–422.
- [72] P.K. Grewal, P.J. Holzfeind, R.E. Bittner, J.E. Hewitt, Mutant glycosyltransferase and altered glycosylation of α -dystroglycan in the myodystrophy mouse, *Nat. Genet.* 28 (2001) 151–154.
- [73] P.J. Holzfeind, P.K. Grewal, H.A. Reitsamer, J. Kechvar, H. Lassmann, H. Hoeger, J.E. Hewitt, R.E. Bittner, Skeletal, cardiac and tongue muscle pathology, defective retinal transmission, and neuronal migration defects in the Large(myd) mouse defines a natural model for glycosylation-deficient muscle–eye–brain disorders, *Hum. Mol. Genet.* 11 (2002) 2673–2687.
- [74] C. Longman, M. Brockington, S. Torelli, C. Jimenez-Mallebrera, C. Kennedy, N. Khalil, L. Feng, R.K. Saran, T. Voit, L. Merlini, C.A. Sewry, S.C. Brown, F. Muntoni, Mutations in the human LARGE gene cause MDC1D, a novel form of congenital muscular dystrophy with severe mental retardation and abnormal glycosylation of α -dystroglycan, *Hum. Mol. Genet.* 12 (2003) 2853–2861.
- [75] M. Kanagawa, F. Saito, S. Kunz, T. Yoshida-Moriguchi, R. Barresi, Y.M. Kobayashi, J. Muschler, J.P. Dumanski, D.E. Michele, M.B. Oldstone, K.P. Campbell, Molecular recognition by LARGE is essential for expression of functional dystroglycan, *Cell* 117 (2004) 953–964.
- [76] R. Barresi, D.E. Michele, M. Kanagawa, H.A. Harper, S.A. Dovico, J.S. Satz, S.A. Moore, W. Zhang, H. Schachter, J.P. Dumanski, R.D. Cohn, I. Nishino, K.P. Campbell, LARGE can functionally bypass α -dystroglycan glycosylation defects in distinct congenital muscular dystrophies, *Nat. Med.* 10 (2004) 696–703.
- [77] B. Cormand, K. Avela, H. Pihko, P. Santavuori, B. Talim, H. Topaloglu, A. de la Chapelle, A.E. Lehesjoki, Assignment of the muscle–eye–brain disease gene to 1p32–p34 by linkage analysis and homozygosity mapping, *Am. J. Hum. Genet.* 64 (1999) 126–135.
- [78] W.B. Dobyns, R.A. Pagon, D. Armstrong, C.J. Curry, F. Greenberg, A. Grix, L.B. Holmes, R. Laxova, V.V. Michels, M. Robinow, et al., Diagnostic criteria for Walker–Warburg syndrome, *Am. J. Med. Genet.* 32 (1989) 195–210.
- [79] S.A. Moore, F. Saito, J. Chen, D.E. Michele, M.D. Henry, A. Messing, R. D. Cohn, S.E. Ross-Barta, S. Westra, R.A. Williamson, T. Hoshi, K.P. Campbell, Deletion of brain dystroglycan recapitulates aspects of congenital muscular dystrophy, *Nature* 418 (2002) 422–425.
- [80] D. Beltran-Valero de Bernabe, S. Currier, A. Steinbrecher, J. Celli, E. van Beusekom, B. van der Zwaag, H. Kayserili, L. Merlini, D. Chitayat, W.B. Dobyns, B. Cormand, A.E. Lehesjoki, J. Cruces, T. Voit, C.A. Walsh, H. van Bokhoven, H.G. Brunner, Mutations in the O-mannosyltransferase gene POMT1 give rise to the severe neuronal migration disorder Walker–Warburg syndrome, *Am. J. Hum. Genet.* 71 (2002) 1033–1043.
- [81] J. van Reeuwijk, S. Maugren, C. van den Elzen, A. Verrips, E. Bertini, F. Muntoni, L. Merlini, H. Scheffer, H.G. Brunner, P. Guicheney, H. van Bokhoven, The expanding phenotype of POMT1 mutations: from Walker–Warburg syndrome to congenital muscular dystrophy, microcephaly, and mental retardation, *Human Mutat.* 27 (2006) 453–459.
- [82] A. D’Amico, A. Tessa, C. Bruno, S. Petrini, R. Biancheri, M. Pane, M. Pedemonte, E. Ricci, A. Falace, A. Rossi, E. Mercuri, F.M. Santorelli, E. Bertini, Expanding the clinical spectrum of POMT1 phenotype, *Neurology* 66 (2006) 1564–1567.
- [83] J. van Reeuwijk, M. Janssen, C. van den Elzen, D. Beltran-Valero de Bernabe, P. Sabatelli, L. Merlini, M. Boon, H. Scheffer, M. Brockington, F. Muntoni, M.A. Huynen, A. Verrips, C.A. Walsh, P.G. Barth, H.G. Brunner, H. van Bokhoven, POMT2 mutations cause α -dystroglycan hypoglycosylation and Walker–Warburg syndrome, *J. Med. Genet.* 42 (2005) 907–912.
- [84] C. Jimenez-Mallebrera, S. Torelli, S.C. Brown, L. Feng, M. Brockington, C.A. Sewry, D. Beltran-Valero De Bernabe, F. Muntoni, Profound skeletal muscle depletion of α -dystroglycan in Walker–Warburg syndrome, *Eur. J. Paediatr. Neurol.* 7 (2003) 129–137.
- [85] D.S. Kim, Y.K. Hayashi, H. Matsumoto, M. Ogawa, S. Noguchi, N. Murakami, R. Sakuta, M. Mochizuki, D.E. Michele, K.P. Campbell, I. Nonaka, I. Nishino, POMT1 mutation results in defective glycosylation and loss of laminin-binding activity in α -DG, *Neurology* 62 (2004) 1011.
- [86] P. Sabatelli, M. Columbaro, I. Mura, C. Capanni, G. Lattanzi, N.M. Maraldi, D. Beltran-Valero de Bernabe, H. van Bokoven, S. Squarzoni, L. Merlini, Extracellular matrix and nuclear abnormalities in skeletal muscle of a patient with Walker–Warburg syndrome caused by POMT1 mutation, *Biochim. Biophys. Acta* 1638 (2003) 57–62.
- [87] B. Cormand, H. Pihko, M. Bayes, L. Valanne, P. Santavuori, B. Talim, R. Gershoni-Baruch, A. Ahmad, H. van Bokhoven, H.G. Brunner, T. Voit, H. Topaloglu, W.B. Dobyns, A.E. Lehesjoki, Clinical and genetic distinction between Walker–Warburg syndrome and muscle–eye–brain disease, *Neurology* 56 (2001) 1059–1069.
- [88] C. Dienes, A. Saarinen, H. Pihko, C. Rosenlew, B. Cormand, W.B. Dobyns, J. Dieguez, L. Valanne, T. Joensuu, A.E. Lehesjoki, POMGnT1 mutation and phenotypic spectrum in muscle–eye–brain disease, *J. Med. Genet.* 41 (2004) e115.
- [89] A. Yoshida, K. Kobayashi, H. Manya, K. Taniguchi, H. Kano, M. Mizuno, T. Inazu, H. Mitsuhashi, S. Takahashi, M. Takeuchi, R. Herrmann, V. Straub, B. Talim, T. Voit, H. Topaloglu, T. Toda, T. Endo, Muscular dystrophy and neuronal migration disorder caused by mutations in a glycosyltransferase, POMGnT1, *Dev. Cell* 1 (2001) 717–724.
- [90] K. Taniguchi, K. Kobayashi, K. Saito, H. Yamanouchi, A. Ohnuma, Y.K. Hayashi, H. Manya, D.K. Jin, M. Lee, E. Parano, R. Falsaperla, P. Pavone, R. Van Coster, B. Talim, A. Steinbrecher, V. Straub, I. Nishino, H. Topaloglu, T. Voit, T. Endo, T. Toda, Worldwide distribution and broader clinical spectrum of muscle–eye–brain disease, *Hum. Mol. Genet.* 12 (2003) 527–534.
- [91] W. Zhang, J. Vajsar, P. Cao, G. Breningstall, C. Dienes, W. Dobyns, R. Herrmann, A.E. Lehesjoki, A. Steinbrecher, B. Talim, T. Toda, H. Topaloglu, T. Voit, H. Schachter, Enzymatic diagnostic test for muscle–eye–brain type congenital muscular dystrophy using commercially available reagents, *Clin. Biochem.* 36 (2003) 339–344.
- [92] J. Vajsar, W. Zhang, W.B. Dobyns, D. Biggar, K.R. Holden, C. Hawkins, P. Ray, A.H. Olney, C.M. Burson, A.K. Srivastava, H. Schachter, Carriers and patients with muscle–eye–brain disease can be rapidly diagnosed by enzymatic analysis of fibroblasts and lymphoblasts, *Neuromuscul. Disord.* 16 (2006) 132–136.

- [93] J. Liu, S.L. Ball, Y. Yang, P. Mei, L. Zhang, H. Shi, H.J. Kaminski, V.P. Lemmon, H. Hu, A genetic model for muscle–eye–brain disease in mice lacking protein O-mannose 1,2-*N*-acetylglucosaminyltransferase (POMGnT1), *Mech. Dev.* 123 (2006) 228–240.
- [94] T. Toda, K. Kobayashi, E. Kondo-Iida, J. Sasaki, Y. Nakamura, The Fukuyama congenital muscular dystrophy story, *Neuromuscul. Disord.* 10 (2000) 153–159.
- [95] T. Nakanishi, M. Sakauchi, Y. Kaneda, H. Tomimatsu, K. Saito, M. Nakazawa, M. Osawa, Cardiac involvement in Fukuyama-type congenital muscular dystrophy, *Pediatrics* 117 (2006) 1187–1192.
- [96] K. Kobayashi, Y. Nakahori, M. Miyake, K. Matsumura, E. Kondo-Iida, Y. Nomura, M. Segawa, M. Yoshioka, K. Saito, M. Osawa, K. Hamano, Y. Sakakihara, I. Nonaka, Y. Nakagome, I. Kanazawa, Y. Nakamura, K. Tokunaga, T. Toda, An ancient retrotransposal insertion causes Fukuyama-type congenital muscular dystrophy, *Nature* 394 (1998) 388–392.
- [97] E. Kondo-Iida, K. Kobayashi, M. Watanabe, J. Sasaki, T. Kumagai, H. Koide, K. Saito, M. Osawa, Y. Nakamura, T. Toda, Novel mutations and genotype-phenotype relationships in 107 families with Fukuyama-type congenital muscular dystrophy (FCMD), *Hum. Mol. Genet.* 8 (1999) 2303–2309.
- [98] F. Silan, M. Yoshioka, K. Kobayashi, E. Simsek, M. Tunc, M. Alper, M. Cam, A. Guven, Y. Fukuda, M. Kinoshita, K. Kocabay, T. Toda, A new mutation of the fukutin gene in a non-Japanese patient, *Ann. Neurol.* 53 (2003) 392–396.
- [99] C. Breton, J. Mucha, C. Jeanneau, Structural and functional features of glycosyltransferases, *Biochimie* 83 (2001) 713–718.
- [100] Y.K. Hayashi, M. Ogawa, K. Tagawa, S. Noguchi, T. Ishihara, I. Nonaka, K. Arahata, Selective deficiency of alpha-dystroglycan in Fukuyama-type congenital muscular dystrophy, *Neurology* 57 (2001) 115–121.
- [101] S. Takeda, M. Kondo, J. Sasaki, H. Kurahashi, H. Kano, K. Arai, K. Misaki, T. Fukui, K. Kobayashi, M. Tachikawa, M. Imamura, Y. Nakamura, T. Shimizu, T. Murakami, Y. Sunada, T. Fujikado, K. Matsumura, T. Terashima, T. Toda, Fukutin is required for maintenance of muscle integrity, cortical histogenesis and normal eye development *Hum. Mol. Genet.* 12 (2003) 1449–1459.
- [102] M. Brockington, D.J. Blake, P. Prandini, S.C. Brown, S. Torelli, M.A. Benson, C.P. Ponting, B. Estournet, N.B. Romero, E. Mercuri, T. Voit, C.A. Sewry, P. Guicheney, F. Muntoni, Mutations in the fukutin-related protein gene (FKRP) cause a form of congenital muscular dystrophy with secondary laminin alpha2 deficiency and abnormal glycosylation of alpha-dystroglycan, *Am. J. Hum. Genet.* 69 (2001) 1198–1209.
- [103] D. Beltran-Valero de Bernabe, T. Voit, C. Longman, A. Steinbrecher, V. Straub, Y. Yuva, R. Herrmann, J. Sperner, C. Korenke, C. Diesen, W.B. Dobyns, H.G. Brunner, H. van Bokhoven, M. Brockington, F. Muntoni, Mutations in the FKRP gene can cause muscle–eye–brain disease and Walker–Warburg syndrome, *J. Med. Genet.* 41 (2004) e61.
- [104] H. Topaloglu, M. Brockington, Y. Yuva, B. Talim, G. Haliloglu, D. Blake, S. Torelli, S.C. Brown, F. Muntoni, FKRP gene mutations cause congenital muscular dystrophy, mental retardation, and cerebellar cysts, *Neurology* 60 (2003) 988–992.
- [105] S.C. Brown, S. Torelli, M. Brockington, Y. Yuva, C. Jimenez, L. Feng, L. Anderson, I. Ugo, S. Kroger, K. Bushby, T. Voit, C. Sewry, F. Muntoni, Abnormalities in alpha-dystroglycan expression in MDC1C and LGMD2I muscular dystrophies, *Am. J. Pathol.* 164 (2004) 727–737.
- [106] E. Mercuri, M. Brockington, V. Straub, S. Quijano-Roy, Y. Yuva, R. Herrmann, S.C. Brown, S. Torelli, V. Dubowitz, D.J. Blake, N.B. Romero, B. Estournet, C.A. Sewry, P. Guicheney, T. Voit, F. Muntoni, Phenotypic spectrum associated with mutations in the fukutin-related protein gene, *Ann. Neurol.* 53 (2003) 537–542.
- [107] F. de Paula, N. Vieira, A. Starling, L.U. Yamamoto, B. Lima, R. de Cassia Pavanello, M. Vainzof, V. Nigro, M. Zatz, Asymptomatic carriers for homozygous novel mutations in the FKRP gene: the other end of the spectrum, *Eur. J. Hum. Genet.* 11 (2003) 923–930.
- [108] T. Harel, Y. Goldberg, S.A. Shalev, I. Chervinski, R. Ofir, O.S. Birk, Limb-girdle muscular dystrophy 2I: phenotypic variability within a large consanguineous Bedouin family associated with a novel FKRP mutation, *Eur. J. Hum. Genet.* 12 (2004) 38–43.
- [109] C.T. Esapa, M.A. Benson, J.E. Schroder, E. Martin-Rendon, M. Brockington, S.C. Brown, F. Muntoni, S. Kroger, D.J. Blake, Functional requirements for fukutin-related protein in the Golgi apparatus, *Hum. Mol. Genet.* 11 (2002) 3319–3331.
- [110] C.T. Esapa, R.A. McIlhinney, D.J. Blake, Fukutin-related protein mutations that cause congenital muscular dystrophy result in ER-retention of the mutant protein in cultured cells, *Hum. Mol. Genet.* 14 (2005) 295–305.
- [111] O. Ullrich, Kongenitale atonisch-sklerotische Muskeldystrophie, ein weiterer Typus der hereditäre Degeneration Erkrankungen des neuromuskulären Systems, *Z. Ges. Neurol. Psychiat.* 126 (1930) 171–201.
- [112] E. Demir, P. Sabatelli, V. Allamand, A. Ferreira, B. Moghadaszadeh, M. Makrelouf, H. Topaloglu, B. Echenne, L. Merlini, P. Guicheney, Mutations in COL6A3 cause severe and mild phenotypes of Ullrich congenital muscular dystrophy, *Am. J. Hum. Genet.* 70 (2002) 1446–1458.
- [113] B. Giusti, L. Lucarini, V. Pietroni, S. Lucoli, B. Bandinelli, P. Sabatelli, S. Squarizoni, S. Petrini, C. Gartioux, B. Talim, F. Roelens, L. Merlini, H. Topaloglu, E. Bertini, P. Guicheney, G. Pepe, Dominant and recessive COL6A1 mutations in Ullrich scleroatonic muscular dystrophy, *Ann. Neurol.* 58 (2005) 400–410.
- [114] T.C. Pan, R.Z. Zhang, D.G. Sudano, S.K. Marie, C.G. Bonnemenn, M.L. Chu, New molecular mechanism for Ullrich congenital muscular dystrophy: a heterozygous in-frame deletion in the COL6A1 gene causes a severe phenotype, *Am. J. Hum. Genet.* 73 (2003) 355–369.
- [115] O.C. Vanegas, R.Z. Zhang, P. Sabatelli, G. Lattanzi, P. Bencivenga, B. Giusti, M. Columbaro, M.L. Chu, L. Merlini, G. Pepe, Novel COL6A1 splicing mutation in a family affected by mild Bethlehem myopathy, *Muscle Nerve* 25 (2002) 513–519.
- [116] H. Hessle, E. Engvall, Type VI collagen. Studies on its localization, structure, and biosynthetic form with monoclonal antibodies, *J. Biol. Chem.* 259 (1984) 3955–3961.
- [117] K. von der Mark, M. van Menxel, H. Weidemann, Isolation and characterization of a precursor form of M collagen from embryonic chicken cartilage, *Eur. J. Biochem.* 138 (1984) 629–633.
- [118] H. Ishikawa, K. Sugie, K. Murayama, M. Ito, N. Minami, I. Nishino, I. Nonaka, Ullrich disease: collagen VI deficiency: EM suggests a new basis for muscular weakness, *Neurology* 59 (2002) 920–923.
- [119] J.C. Atkinson, M. Ruhl, J. Becker, R. Ackermann, D. Schuppan, Collagen VI regulates normal and transformed mesenchymal cell proliferation in vitro. *Exp. Cell Res.* 228 (1996) 283–291.
- [120] M. Ruhl, M. Johannsen, J. Atkinson, D. Manski, E. Sahin, R. Somasundaram, E.O. Riecken, D. Schuppan, Soluble collagen VI induces tyrosine phosphorylation of paxillin and focal adhesion kinase and activates the MAP kinase erk2 in fibroblasts, *Exp. Cell Res.* 250 (1999) 548–557.
- [121] M. Ruhl, E. Sahin, M. Johannsen, R. Somasundaram, D. Manski, E.O. Riecken, D. Schuppan, Soluble collagen VI drives serum-starved fibroblasts through S phase and prevents apoptosis via down-regulation of Bax, *J. Biol. Chem.* 274 (1999) 34361–34368.
- [122] E. Mercuri, Y. Yuva, S.C. Brown, M. Brockington, M. Kinali, H. Jungbluth, L. Feng, C.A. Sewry, F. Muntoni, Collagen VI involvement in Ullrich syndrome: a clinical, genetic, and immunohistochemical study, *Neurology* 58 (2002) 1354–1359.
- [123] E. Demir, A. Ferreira, P. Sabatelli, V. Allamand, S. Makri, B. Echenne, M. Maraldi, L. Merlini, H. Topaloglu, P. Guicheney, Collagen VI status and clinical severity in Ullrich congenital muscular dystrophy: phenotype analysis of 11 families linked to the COL6 loci, *Neuropediatrics* 35 (2004) 103–112.
- [124] S. Squarizoni, P. Sabatelli, N. Bergamin, P. Guicheney, E. Demir, L. Merlini, G. Lattanzi, A. Ognibene, C. Capanni, E. Mattioli, M. Columbaro, P. Bonaldo, N.M. Maraldi, Ultrastructural defects of collagen VI filaments in an Ullrich syndrome patient with loss of the alpha3(VI) N10-N7 domains, *J. Cell. Physiol.* 206 (2006) 160–166.
- [125] E. Mercuri, A. Lampe, J. Allsop, R. Knight, M. Pane, M. Kinali, C. Bonnemenn, K. Flanigan, I. Lapini, K. Bushby, G. Pepe, F. Muntoni, Muscle MRI in Ullrich congenital muscular dystrophy and Bethlehem myopathy, *Neuromuscul. Disord.* 15 (2005) 303–310.

- [126] M. Brockington, S.C. Brown, A. Lampe, Y. Yuva, L. Feng, C. Jimenez-Mallebrera, C.A. Sewry, K.M. Flanigan, K. Bushby, F. Muntoni, Prenatal diagnosis of Ullrich congenital muscular dystrophy using haplotype analysis and collagen VI immunocytochemistry, *Prenat. Diagn.* 24 (2004) 440–444.
- [127] U.C. Reed, L.G. Ferreira, E.C. Liu, M.B. Resende, M.S. Carvalho, S.K. Marie, M. Scaff, Ullrich congenital muscular dystrophy and Bethlem myopathy: clinical and genetic heterogeneity, *Arq. Neuro-Psiquiatr.* 63 (2005) 785–790.
- [128] A.K. Lampe, D.M. Dunn, A.C. von Niederhausern, C. Hamil, A. Aoyagi, S.H. Laval, S.K. Marie, M.L. Chu, K. Swoboda, F. Muntoni, C.G. Bonnemann, K.M. Flanigan, K.M. Bushby, R.B. Weiss, Automated genomic sequence analysis of the three collagen VI genes: applications to Ullrich congenital muscular dystrophy and Bethlem myopathy, *J. Med. Genet.* 42 (2005) 108–120.
- [129] J. Kirschner, I. Hausser, Y. Zou, G. Schreiber, H.J. Christen, S.C. Brown, I. Anton-Lamprecht, F. Muntoni, F. Hanefeld, C.G. Bonnemann, Ullrich congenital muscular dystrophy: connective tissue abnormalities in the skin support overlap with Ehlers–Danlos syndromes, *Am. J. Med. Genet., Part A* 132 (2005) 296–301.
- [130] P. Bonaldo, P. Braghetta, M. Zanetti, S. Piccolo, D. Volpin, G.M. Bressan, Collagen VI deficiency induces early onset myopathy in the mouse: an animal model for Bethlem myopathy, *Hum. Mol. Genet.* 7 (1998) 2135–2140.
- [131] W.A. Irwin, N. Bergamin, P. Sabatelli, C. Reggiani, A. Megighian, L. Merlini, P. Braghetta, M. Columbaro, D. Volpin, G.M. Bressan, P. Bernardi, P. Bonaldo, Mitochondrial dysfunction and apoptosis in myopathic mice with collagen VI deficiency, *Nat. Genet.* 35 (2003) 367–371.
- [132] F. Usuki, A. Yamashita, I. Kashima, I. Higuchi, M. Osame, S. Ohno, Specific inhibition of nonsense-mediated mRNA decay components, SMG-1 or Upf1, rescues the phenotype of ullrich disease fibroblasts, *Mol. Ther.* 14 (2006) 351–360.
- [133] V. Allamand, P. Richard, A. Lescure, C. Ledeuil, D. Desjardin, N. Petit, C. Gartioux, A. Ferreira, A. Krol, N. Pellegrini, J.A. Urtizberea, P. Guicheney, A single homozygous point mutation in a 3′ untranslated region motif of selenoprotein N mRNA causes SEPNI-related myopathy, *EMBO Rep.* 7 (2006) 450–454.
- [134] B. Moghadaszadeh, N. Petit, C. Jaillard, M. Brockington, S.Q. Roy, L. Merlini, N. Romero, B. Estournet, I. Desguerre, D. Chaigne, F. Muntoni, H. Topaloglu, P. Guicheney, Mutations in SEPNI cause congenital muscular dystrophy with spinal rigidity and restrictive respiratory syndrome, *Nat. Genet.* 29 (2001) (2003) 17–18.
- [135] N. Petit, A. Lescure, M. Rederstorff, A. Krol, B. Moghadaszadeh, U.M. Wewer, P. Guicheney, Selenoprotein N: an endoplasmic reticulum glycoprotein with an early developmental expression pattern, *Hum. Mol. Genet.* 12 (2003) 1045–1053.
- [136] A. Ferreira, S. Quijano-Roy, C. Pichereau, B. Moghadaszadeh, N. Goemans, C. Bonnemann, H. Jungbluth, V. Straub, M. Villanova, J.P. Leroy, N.B. Romero, J.J. Martin, F. Muntoni, T. Voit, B. Estournet, P. Richard, M. Fardeau, P. Guicheney, Mutations of the selenoprotein N gene, which is implicated in rigid spine muscular dystrophy, cause the classical phenotype of multimimic disease: reassessing the nosology of early-onset myopathies, *Am. J. Hum. Genet.* 71 (2002) 739–749.
- [137] A. Ferreira, C. Ceuterick-de Groote, J.J. Marks, N. Goemans, G. Schreiber, F. Hanefeld, M. Fardeau, J.J. Martin, H.H. Goebel, P. Richard, P. Guicheney, C.G. Bonnemann, Desmin-related myopathy with Mallory body-like inclusions is caused by mutations of the selenoprotein N gene, *Ann. Neurol.* 55 (2004) 676–686.
- [138] E. Mercuri, B. Talim, B. Moghadaszadeh, N. Petit, M. Brockington, S. Counsell, P. Guicheney, F. Muntoni, L. Merlini, Clinical and imaging findings in six cases of congenital muscular dystrophy with rigid spine syndrome linked to chromosome 1p (RSM1), *Neuromuscul. Disord.* 12 (2002) 631–638.
- [139] Y. Okamoto, H. Takashima, I. Higuchi, W. Matsuyama, M. Suehara, Y. Nishihira, A. Hashiguchi, R. Hirano, A.R. Ng, M. Nakagawa, S. Izumo, M. Osame, K. Arimura, Molecular mechanism of rigid spine with muscular dystrophy type 1 caused by novel mutations of selenoprotein N gene, *Neurogenetics* (2006) [Epub ahead of print].
- [140] D.J. Burkin, S.J. Kaufman, The alpha7beta1 integrin in muscle development and disease, *Cell Tissue Res.* 296 (1999) 183–190.
- [141] T. Velling, G. Collo, L. Sorokin, M. Durbeej, H. Zhang, D. Gullberg, Distinct alpha 7A beta 1 and alpha 7B beta 1 integrin expression patterns during mouse development: alpha 7A is restricted to skeletal muscle but alpha 7B is expressed in striated muscle, vasculature, and nervous system, *Dev. Dyn.* 207 (1996) 355–371.
- [142] P.T. Martin, S.J. Kaufman, R.H. Kramer, J.R. Sanes, Synaptic integrins in developing, adult, and mutant muscle: selective association of alpha1, alpha7A, and alpha7B integrins with the neuromuscular junction, *Dev. Biol.* 174 (1996) 125–139.
- [143] U. Mayer, G. Saher, R. Fassler, A. Bornemann, F. Echtermeyer, H. von der Mark, N. Miosge, E. Poschl, K. von der Mark, Absence of integrin alpha 7 causes a novel form of muscular dystrophy, *Nat. Genet.* 17 (1997) 318–323.
- [144] N.L. Flintoff-Dye, J. Welser, J. Rooney, P. Scowen, S. Tamowski, W. Hatton, D.J. Burkin, Role for the alpha7beta1 integrin in vascular development and integrity, *Dev. Dyn.* 234 (2005) 11–21.
- [145] W. Wang, W. Wu, T. Desai, D.C. Ward, S.J. Kauffman, Localization of the alpha 7 integrin gene (ITGA7) on human chromosome 12q13: clustering of integrin and Hox genes implies parallel evolution of these gene families, *Genomics* 26 (1995) 568–570.
- [146] Y.K. Hayashi, F.L. Chou, E. Engvall, M. Ogawa, C. Matsuda, S. Hirabayashi, K. Yokochi, B.L. Ziober, R.H. Kramer, S.J. Kaufman, E. Ozawa, Y. Goto, I. Nonaka, T. Tsukahara, J.Z. Wang, E.P. Hoffman, K. Arahata, Mutations in the integrin alpha7 gene cause congenital myopathy, *Nat. Genet.* 19 (1998) 94–97.
- [147] D.J. Burkin, G.Q. Wallace, D.J. Milner, E.J. Chaney, J.A. Mulligan, S.J. Kauffman, Transgenic expression of {alpha}7{beta}1 integrin maintains muscle integrity, increases regenerative capacity, promotes hypertrophy, and reduces cardiomyopathy in dystrophic mice, *Am. J. Pathol.* 166 (2005) 253–263.
- [148] D.J. Burkin, G.Q. Wallace, K.J. Nicol, D.J. Kaufman, S.J. Kauffman, Enhanced expression of the alpha 7 beta 1 integrin reduces muscular dystrophy and restores viability in dystrophic mice, *J. Cell Biol.* 152 (2001) 11218–12007.
- [149] J.E. Rooney, J.V. Welser, M.A. Dechert, N.L. Flintoff-Dye, S.J. Kaufman, D.J. Burkin, Severe muscular dystrophy in mice that lack dystrophin and {alpha}7 integrin, *J. Cell. Sci.* 119 (2006) 2185–2195.